



ORIGINAL PAPER

Anthropology

Evaluation of porcine decomposition and total body score (TBS) in a central European temperate forest

Lara Indra MSc¹  | Stephanie Giles PhD²  | Clara Alfsdotter PhD³  |
David Errickson PhD²  | Sandra Lösch PhD¹ 

¹Department of Anthropology, Institute of Forensic Medicine, University of Bern, Bern, Switzerland

²Cranfield Forensic Institute, Cranfield University, Cranfield, UK

³National Forensic Centre, Swedish Police Authority, Linköping, Sweden

Correspondence

Sandra Lösch, Department of Anthropology, Institute of Forensic Medicine, University of Bern, Murtenstrasse 26, Bern CH-3008, Switzerland.
Email: sandra.loesch@irm.unibe.ch

Abstract

The total body score (TBS) is a visual scoring method to scale the succession of decomposition stages. It compares decomposition between cadavers, to connect it with external taphonomic factors and estimate the post-mortem interval. To study decomposition in various climatic environments, pigs are often used as human proxies. Currently, there is one TBS system by Keough et al. (*J Forensic Sci.* 2017;62:986) for surface-deposited domestic pigs, coming from South Africa. Our study aims to evaluate this method and analyze porcine decomposition in Central Europe to inform forensic research and casework. We conducted an experiment studying six 50 kg pig carcasses in a temperate Swiss forest. Three observers documented decomposition patterns and rated the decomposition stages from photographs based on the porcine TBS model by Keough et al. (*J Forensic Sci.* 2017;62:986). We documented discrepancies between the carcass decomposition of our specimens and those in the South African study, especially related to the high insect activity in our experiment. Furthermore, we noted factors complicating TBS scoring, including rainfall and scavengers. The agreement between TBS observers from photographs was in the highest agreement category apart from one “substantial agreement” category. Our study is the first in Europe to systematically test the Keough et al. (*J Forensic Sci.* 2017;62:986) method. The results evidence that regional adaptations are required to be applicable for other environments. We present a modified approach based on experimental observations in a Swiss temperate forest. The identification of regional decomposition patterns and drivers will inform future taphonomy research as well as forensic casework in comparable contexts in Central Europe.

KEYWORDS

decomposition, forensic anthropology, forensic taphonomy, pig carcass, postmortem interval (PMI), total body score (TBS)

Highlights

- Our experiment tested the total body score (TBS) method in Central Europe (Switzerland).
- Inter-observer agreement was high when rating porcine TBS from photographs.

This is an open access article under the terms of the [Creative Commons Attribution-NonCommercial](https://creativecommons.org/licenses/by-nc/4.0/) License, which permits use, distribution and reproduction in any medium, provided the original work is properly cited and is not used for commercial purposes.

© 2024 The Authors. *Journal of Forensic Sciences* published by Wiley Periodicals LLC on behalf of American Academy of Forensic Sciences.

- The Keough et al. (2017) TBS system was not directly applicable.
- We developed a modified TBS approach for pig scoring in a temperate forest.
- We identified regional decomposition patterns and drivers to inform forensic practice.

1 | INTRODUCTION

Forensic practitioners often use decomposition stages to qualitatively describe the state of human remains. A five-stage gross decomposition model was published by Galloway and colleagues based on medico-legal cases from Arizona, USA, published in 1989 [1]. This model was modified by Megyesi and colleagues in 2005 with a retrospective study on casework from various states across the USA, resulting in four broad decomposition stages (1. Fresh, 2. Early decomposition, 3. Advanced decomposition, and 4. Skeletonization) that are combined with the total body score (TBS) [2]. Every phase within a stage is described by a range of characteristics and assigned scores of between 1 and 13 points that exponentially increase as decomposition progresses. The decomposition phases of three body regions (head/neck, trunk, and limbs) are scored independently and the sum of these three partial body scores generates the TBS [2]. This approach was developed to overcome the challenge of variable decomposition patterns and rates between body regions (differential decomposition) [2]. However, issues related to decomposition variation *within* a given body region can remain, as the stages are assigned through a “best-fit” approach that includes multiple decomposition traits per stage.

For Central Europe, published experimental taphonomic studies on exposed remains are relatively rare and focused on forensic entomology [3–6], muscle protein degradation for PMI estimation [5, 7], and soil analyses [8–11]. Some used the Keough et al. [12] scoring system [6, 7], and some briefly described the results of the Megyesi et al. [2] system applied to pig carcasses [5, 13]. However, up to now, there is no systematic evaluation of the Keough et al. [12] system for a Central European context.

Human taphonomy research facilities are established in the USA, Canada, Australia, and the Netherlands [14]. However, such experimental work on exposed humans is not feasible in many other countries, including Switzerland [15]. Therefore, taphonomic studies on exposed human remains in Europe are often performed retrospectively from medico-legal casework or with various non-human species as substitutes, in particular, domestic pigs (*Sus scrofa domesticus*) [16–20]. Despite anatomical and physiologic differences between humans and pigs [16, 21, 22], domestic pigs are often studied as proxies because of their comparable skin, body composition, weight range, physiology, and gut microbiota [16, 20, 21, 23–25]. With non-human carcasses, researchers can control for body size, PMI, or cause of death and thus, obtain a more homogenous selection compared to retrospective studies conducted on medico-legal cases [16]. Several experimental studies on pig carcasses have applied the Megyesi et al. [2] human total body scoring (TBS) system, largely without discussing the limitations of doing so, for example,

[21, 22, 24, 26, 27]. The first study to present a modified version for pigs was by Lynch-Aird and colleagues in 2015 [28], although, exclusively for the use of hanging pig carcasses. The first publication to systematically evaluate the human TBS method and propose amendments for surface-deposited pigs was Keough and colleagues based on a study in South Africa in 2017 [12]. For example, they found a pink or red lividity being present in the fresh pig bodies, which is not mentioned for humans in Megyesi et al. [2]. Since the Keough et al. [12] amendments were published, several experimental decomposition studies applied their scoring system [6, 7, 19, 29–31]. However, even with this method, there are limitations for the use of surface-deposited pig carcasses. For instance, Hill and Pokines [2022] noted the necessity of a porcine rather than a human system to rate pigs [29]. Furthermore, they concluded that the Keough et al. [12] system is not suitable for buried, wrapped or fetal-sized pig remains [29]. The majority of pig decomposition studies keep using the Megyesi et al. TBS method [5, 21, 22, 24, 25, 32–34].

Furthermore, studies have tested whether there are differences between TBS rating by different observers [19, 35] and between rating the carcass in real-time versus from photographs [19, 36]. They conclude that the inter-observer agreement is high overall for the Megyesi et al. [2] and the Keough et al. [12] methods [19, 35, 36], and that photographs yield a higher inter-observer agreement than real-time observations [36]. Moreover, the photographic scoring of pig carcasses was found to work better with the method of Keough and colleagues [19].

Another important aspect of decomposed human remains in a forensic context is the post-mortem interval (PMI) [37]. Time-since-death estimation is often crucial as it can help to describe the forensic relevance of the remains and, therefore, to decide whether further legal investigations are needed [38, 39]. Moreover, information of the PMI can support the individual's personal identification process or aid in the reconstruction of circumstances surrounding death [40]. To estimate PMI, Vass et al. [41] introduced the existing system of accumulated degree days (ADD) into forensic decomposition research [41]. With this approach, the daily average ambient temperature is collected from the minimum and maximum temperature of 24h-intervals in the postmortem period. Temperature is one of the main variables accounting for variation in decomposition [2, 42] and by standardizing the effect of temperature on decay using ADD, different geographical, seasonal, and environmental settings are made more comparable. Megyesi et al. [2] were the first to combine the TBS system with the ADD approach for the purpose of PMI estimation [2].

As research in forensic taphonomy has progressed, we now know that regional variability is a major aspect, thus, showing the need for studies from different parts of the world to improve decomposition

assessments. Experimental studies on non-human mammals can contribute to the understanding of regional differences in decomposition patterns and, subsequently, inform forensic casework. It is therefore relevant to have appropriate, regional-specific decomposition scoring systems [43]. So far, there are only two TBS methods published for pig carcasses, one from South Africa [12] and one from the USA [28]. However, with the amount of forensic taphonomy studies on humans and pigs rising [18, 44], there is a need for regionally adapted methods. Therefore, the aim of our study is threefold:

1. to document porcine decomposition during summer through fall in a Central European (Swiss) temperate forest in order to direct future experiments and inform forensic casework;
2. to compare decomposition patterns at our site with those by Keough et al. [12] and evaluate the applicability of their TBS system to a Central European (Swiss) context;
3. to evaluate the intra- and inter-observer agreement for TBS rating after Keough et al. [12] from photographs.

2 | MATERIALS AND METHODS

2.1 | Study site and carcasses

We set up the study in Switzerland near the city of Bern in Krauchthal (on a hill called "Geissmont," 46°59'37.0"N; 7°33'58.9"E, altitude ca. 750m), in a temperate mixed forest on mainly brown Earth and within the humid temperate climate zone (Cfb in the Köppen-Geiger classification [45]). Our study interval was from June 18, 2021 to November

14, 2021, with an average daily temperature of 15.1°C (annual average of 9.3°C between 1991 and 2020), and mean total rainfall of 454mm (mean annual total of 1021mm between 1991 and 2020) [46, 47].

We studied six juvenile domestic pig (*Sus scrofa domesticus*) carcasses (P1–P6) weighing 50kg ± 1kg. The specimens (intended for food consumption) were bought from a local meat producer, where they had been stunned and euthanized by electric shocks to the head and heart, respectively, in compliance with the Swiss National Animal Protection Ordinance [48]. About 4h elapsed between their death and placement on the experiment site on June 18, 2021, during which the pigs were lying in the open and within an uncooled truck. We exposed three of the pigs (P1, P3, P5) and covered the other three (P2, P4, P6) in a zinc-plated wire cage of 5cm × 5cm mesh size, to limit scavenging by large vertebrates as recommended previously [17, 18, 49]. All six pigs were placed on a metal grid to allow for efficient soil sampling beneath them with as little carcass movement as possible. Due to limited space in the area, we placed two pigs (P3, P4) on a sun-exposed plot, while the other pigs (P1, P2, P5, P6) were under a tree cover (Figure 1). In addition, we included three plots without pigs to control for scavenging and soil biology changes, but these control plots are not further handled in this study. All pigs were placed at least 50m linear distance from each other to ensure independent decomposition processes [16, 50]. We left the pigs on-site for approximately 5 months (149 days) during summer and fall, with motion-sensitive wildlife camera traps (Braun Scouting Camera Black 1300 and Crenova Trail Camera 4K) recording vertebrate activity around the carcasses 24h a day for the duration of the study. We used post-depositional days (PDD) to report the number of days after the experiment started, for example, PDD 1 refers to 1 day after the pig deposition.

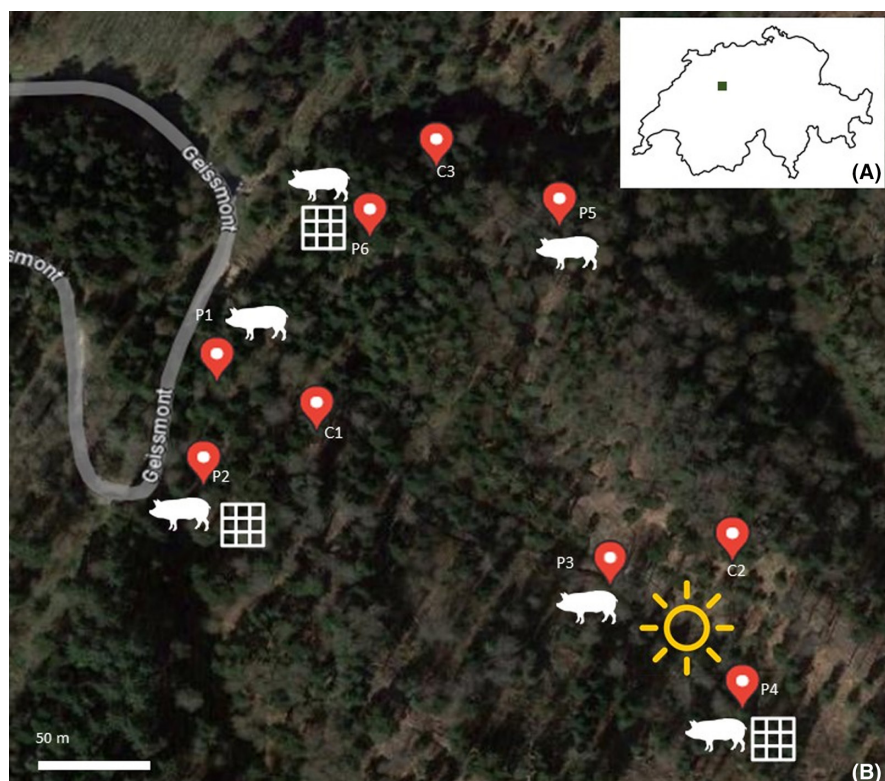


FIGURE 1 The location of the experiment at the Geissmont site in Switzerland (A) and the positions and variables of the nine plots (B). P indicating pig plots, C control plots, the grids indicate caged specimens.

2.2 | Decomposition

A total of 31 site visits of 30–60 min were conducted, all by the first author (LI), and additional helpers in about half of the visits. The visit frequency was as follows: daily (PDD 1–10), every second day (PDD 12–20), every third day (PDD 20–38), weekly (PDD 38–66), and biweekly (PDD 66–149) (Figure 2). During each site visit, the pig carcasses were photographed in situ with a handheld digital camera (Olympus E-M5 Mark III 350 dpi and at PDD 20 an Olympus TG-6, 315 dpi). We started with a perpendicular picture from above with the entire carcass and its identification tag in plan view, and then detailing the different body parts and any specific taphonomic detail from various angles, similar to the approach described by Ribéreau-Gayon et al. [19]. On average, we took 16 pictures per pig and visit day. On each field day, we performed non-invasive (documentation, SD-card changes of camera traps) and minimally invasive (documentation, SD-card changes of camera traps, collection of entomological samples) procedures, and in total five invasive interventions (soil sampling below pig).

One of the authors (LI) with less than 1 year experience scoring decomposition on humans and pigs rated the TBS of the pig carcasses following the Keough et al. [12] scoring system. This was done retrospectively from the colored photographs taken at each site visit in order to minimize the time of human presence in the field. In case of differential decomposition of the fore and hind limbs, the scores of the four limbs were averaged.

Following the recommendations by Megyesi et al. [2], we calculated accumulated degree days (ADD) as the sum of daily temperature averages in degree Celsius from death to scoring day (day starting at 00:00). We used three data loggers (ELV PDF Datalogger UTD100) in this study, attached to each of the three carcass cages, for collection of hourly temperature data. We collected daily mean humidity and rainfall data throughout the study and hourly temperatures from PMI 80 onward from a national meteorological station located at 553 m altitude and ca. 7.5 km away from our site. We used these data without applying a correction factor for calibration despite the distance to our site, following previously recommended procedures [51].

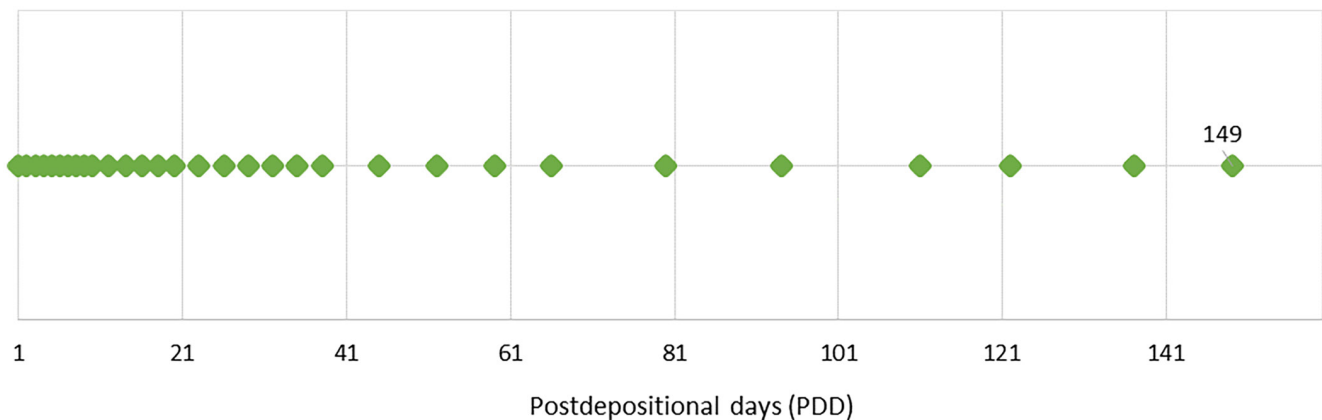


FIGURE 2 Site visit frequency. We photographically documented all six pigs from the Geissmont site daily for 10 days, every second day for 10 days, every third day for 18 days, weekly for 4 weeks, and biweekly for 6 weeks.

We conducted a two-way analysis of variance (ANOVA) to assess whether direct sunlight and the presence of cages influenced the ADD values. To do so, we followed the methodology applied by Forbes et al. [34]. Accordingly, we selected five TBS values (6, 13, 23, 25, and 31) that were most often scored among the six pigs and that represented different stages throughout decomposition and conducted the ANOVA at each of these values.

2.3 | Intra-/inter-observer agreement

For the evaluation of the intra-observer error, rater 1 (LI) scored the photographs of all six pigs at all 31 site visit days twice, with a five-week break between the rating blocks. For the inter-observer agreement, raters 2 and 3 (the authors SG and CA), both taphonomy researchers with several years of TBS rating experience on humans, each scored photos of all six pigs at four selected post-mortem days: PDD 1, 10, 20, and 80. These days were chosen to represent various stages throughout the experiment. We tested intra-observer reliability with the weighted Cohen Kappa [52], interpreting the results as suggested by Landis and Koch [53]. Similar to a previous study [19], we evaluated the inter-observer agreement with the intraclass correlation coefficient (ICC, two-way random model) [54], the interpretation following Koo and Li [54]. The analyses were performed with the software “Statistical Package for Social Sciences” (SPSS, v. 27.0, IBM, Armonk, NY, USA).

All data supporting this study are included within the article.

3 | RESULTS

The temperature and precipitation data for the duration of the experiment are shown in Figure 3. Mean daily temperatures ranged between 1.9 and 23.7°C (mean of $14.4 \pm 5.4^\circ\text{C}$), rainfall between 0 and 48.3 mm per day (total 577.9 mm, mean of 3.9 ± 8.3 mm), and humidity as measured at the nearby meteorological station ranged from 45.9% to 98.3% (mean of $79.3 \pm 9.8\%$).

3.1 | Decomposition

All six pigs had entered the early decomposition stage 1 day after placement (PDD 1) and all samples had reached some stage of skeletonization before the study ceased. The heads skeletonized first in all but one pig (a desiccated skin flap covered the skull bones of P3 until PDD 23), followed by either limbs, or limbs and trunk concurrently. Similarly, due to persisting mummified skin covering more than half of the scored area, two partial body scores did not reach the level of skeletonization: the skull/neck of P2 (caged, shaded) and

trunk of P4 (caged, sun-exposed). Table 1 presents the decomposition stages rated for all pigs and body areas, and Figure 4 shows the TBS and ADD values over time.

Insect activity started at the mouth, eyes, and nose right after deposition and maggot feeding proceeded rapidly from there (Figure 5A). The skull reached skeletonization after 6–26 days (mean of 12.3 ± 6.7 days), usually while the rest of the body was still in early decomposition. In P2, the advanced decomposition stage of the head and neck region was skipped entirely due to larval feeding. Following the dark-red discoloration, half of the pigs (P3, P4, and P5)

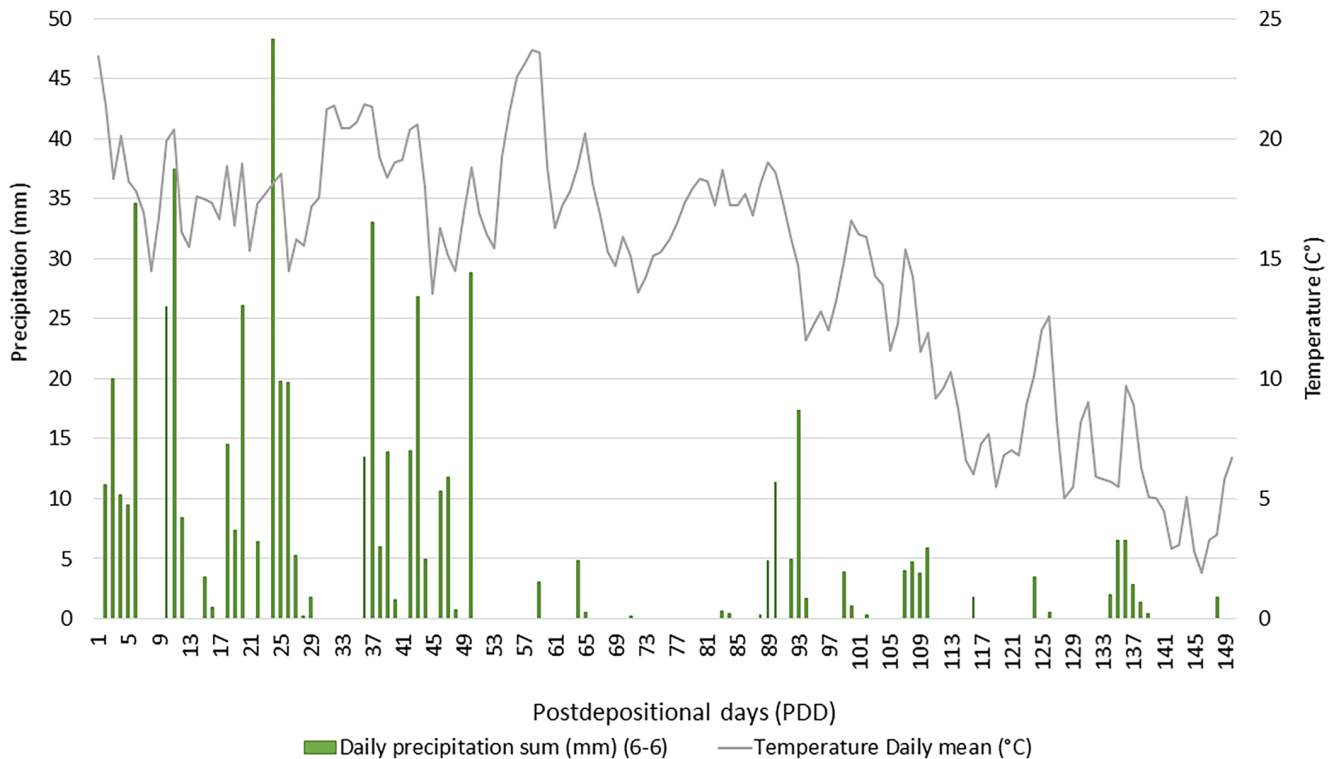


FIGURE 3 Rainfall (mm per day) and mean temperature (°C) for the duration of the experiment.

TABLE 1 Decomposition stages of all six pig carcasses (P1–P6) with the according postmortem interval (in post-depositional days, PDD) and duration of the stages in days. In total, our experimental study lasted 149 days. The stages are based on TBS ratings following Keough et al. [12].

Pig No.	Body region	Early decomposition		Advanced decomposition		Skeletonization	
		PDD	Duration	PDD	Duration	PDD	Duration
P1	Head/neck	1-4	4	5-10	6	12	138
	Trunk	1-12	12	14-59	46	66	84
	Limbs	1-12	12	14	2	16	134
P2	Head/neck	1-5	5	6-149	144	0	0
	Trunk	1-10	10	12-23	12	26	124
	Limbs	1-10	10	12-18	7	20	130
P3	Head/neck	1-4	4	5-23	12	26	124
	Trunk	1-4	4	5-20	16	23	127
	Limbs	1-7	7	8-16	9	18	132
P4	Head/neck	1-3	3	4-5	2	6	144
	Trunk	1-6	6	7-149	143	0	0
	Limbs	1-5	5	6-14	9	16	134
P5	Head/neck	1-3	3	4-10	7	12	138
	Trunk	1-10	10	12-18	7	20	130
	Limbs	1-10	10	12-18	7	20	130
P6	Head/neck	1-6	6	7-10	4	12	138
	Trunk	1-10	10	12-18	7	20	130
	Limbs	1-10	10	12-18	7	20	130

exhibited a gray to green color in the facial region before maggots ate away the soft tissue (Figure 5B). Edema of the ears was not or only slightly present and the ears were frequently filled with rainwater during the early stages (Figure 5C).

FIGURE 4 TBS values scored after Keough et al. [12] for all six pigs (P1–P6), plotted against mean ADD and time (postdepositional days, PDD).

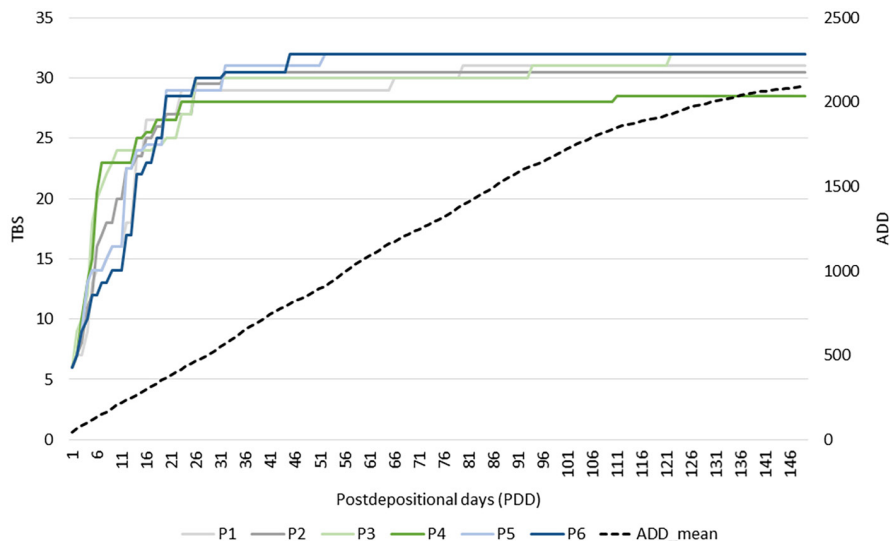


FIGURE 5 Selected findings observed in our study: (A) early maggot colonization of the head and neck, (B) gray to green discoloration of the facial area in P5, (C) water collecting in the auricle of P5, (D) anal region with high larval activity in P1, (E) differential decomposition of the fore and hind limbs in P4, and (F) shiny skin (black arrow) and tag cord cutting into the skin (white arrow) due to bloating of the limb in P4.




FIGURE 6 P4 at post-depositional day (PDD) 26 (left) with leathery skin, and 3 days later at PDD 29 (right) with soaked skin after precipitation.

the neck into the thorax, preventing full bloat of the carcasses. Pigs in sun and shade plots differed in some aspects. For instance, the sun-exposed pigs (P3, P4) entered the advanced decomposition stage of the trunk earlier (at a PDD of 5–7 days) than the shaded pigs (at a PDD of 12–14 days). In addition, shaded pigs showed gray-green discoloration of the abdomen up to PDD 12 before turning to a purple-black color, while for the sun-exposed pigs, no gray-green color was noted on any visit but rather a darker color directly. P1 and P4 in particular remained with relatively large areas of desiccated skin until PDD 59 and PDD 149 (end of study), respectively, preventing the view to inner structures and thus complicating the scoring.

We observed differential decomposition between the forelimbs and the hind limbs in all pigs, with the forelimbs decomposing faster (Figure 5E), resulting in quicker skeletonization due to increased maggot masses proceeding through this part from the head region. Therefore, the hind limbs were more susceptible to mummification. The opposite was the case in pig P3, where all limbs decomposed at the same rate but one of the forelimbs remained mummified thereafter. Furthermore, we noted bloating in the entire limbs, including the mid- and distal parts (Figure 5F), and observed a leathery skin appearance of the limbs only after advanced decomposition started.

Scavenging was recorded by camera traps. The skin of P1 was removed by a red fox (*Vulpes vulpes*) at PDD 64, causing a step back in the TBS scoring from advanced decomposition (8pts) to skeletonization (9pts). The only other scavengers were small rodents that did not have a visible effect on decomposition. In some instances, the skin rehydrated after precipitation and scores went from “mummified” (9pts) back to “moist decomposition” (8pts) on the following scoring day (Figure 6).

Tables 2–4 summarize our observed differences from the TBS table by Keough et al. [12]. We thus present an amended version for further evaluation in a temperate forest environment in future studies. We modified the content of the Keough et al. [12] scoring system especially in the fresh and early decomposition stages, with one addition for the advanced decomposition of the head/neck section and one in the skeletonized phase of the limbs.

We found no statistically significant bias between ADD values of caged and exposed pigs at any of the selected TBS. However, direct sunlight affected the ADD at the earliest tested TBS 6, but not thereafter (Table 5).

3.2 | Intra-/inter-observer agreement

The intra-observer agreement of TBS ratings based on the Keough et al. [12] approach ranged from substantial to almost perfect. The inter-observer agreement is excellent throughout (Table 6). The only agreement that is not in the highest category is the intra-observer agreement at P4 (“substantial agreement”).

4 | DISCUSSION

Our paper focuses on porcine decomposition patterns in a summer/fall temperate Central European (Swiss) forest. We aimed to test the applicability of the total body score (TBS) method developed specifically for and from surface-deposited pig carcasses in forensic research [12].

4.1 | Decomposition and scoring

When comparing the macroscopic decomposition changes of our pigs to that of the specimens in Keough et al. [12], notable differences are apparent (Tables 2–4). Firstly, our pig carcasses showed none or only faint edema of the ears. This might be due to rainwater accumulation in the auricles in the Swiss sample, cooling them down and thus inhibiting bacterial growth. In addition, Keough et al. [12] noted bloating solemnly of the proximal aspects of the limbs, while our specimens exhibited bloating of the entire limbs. Moreover, the limbs of our specimens exhibited a stage where desiccated tissue covered less than half of the area scored. The descriptions in the Keough et al. [12] approach do not account for this state. In addition, some descriptions by Keough et al. [12] include the conjunction “and” or “with,” implying that two characteristics have to be present simultaneously in order to score that category. For example, Keough et al. [12] describe “drying of lips, nose and ears,” or “marbling of abdomen with maximum bloat.” Nevertheless, oftentimes we did not observe this co-association but rather only one of the characteristics at a time, for instance, the nose being dried out but the ears still fresh. Attempts to overcome the issue of co-associated variables have been undertaken already, for example, by using independent scoring systems or gradable decomposition markers, and show potential for further evaluation [43, 55, 56].

TABLE 2 Porcine partial body scoring for the head/neck by Keough et al. [12] and our suggested modifications for future applications in temperate forest environments.

		Keough et al. (2017)	This study
A. Fresh			
(1 pt)	1	Fresh, no discoloration – slight lividity (pink/red)	n/a
B. Early decomposition			
(2pts)	1	Insect activity; pronounced lividity (dark pink/red)	n/a
(3pts)	2	Dark-red discoloration with some flesh still relatively fresh; edema of ears; maggot colonization (mouth); initial bloating of neck and skin slippage	Possible gray-green discoloration, some flesh still relatively fresh, maggot colonization (mouth)
(4pts)	3	Discoloration and/or brownish shades particularly at edges, drying of nose, ears, and lips; prominent bloating of neck; maggot colonization (mouth and eyes); purging of decompositional fluids (mouth)	Drying of nose, slight bloating of neck, hair loss and skin slippage, maggot colonization (mouth and eyes), ears might still be fresh
(5pts)	4	Purging of decompositional fluids (mouth, eyes, nose); brown discoloration; hair loss and skin slippage; drying of lips, nose and ears	Dark discoloration, extensive maggot colonization
(6pts)	5	Black discoloration of flesh; extensive maggot colonization and migration	Dark green-gray or purple-black discoloration of flesh, extensive maggot colonization and migration
C. Advanced decomposition			
(7pts)	1	Caving in of the flesh and tissues of eyes and throat	Caving in of the flesh and tissues of eyes and throat, ears might still be fresh
(8pts)	2	Moist decomposition with bone exposure less than half the area being scored	n/a
(9pts)	3	Mummification with bone exposure less than half the area being scored	n/a
D. Skeletonization			
(10pts)	1	Bone exposure of more than half the area being scored with greasy substances and decomposed tissue	n/a
(11pts)	2	Bone exposure of more than half the area being scored with desiccation of mummified tissue	n/a
(12pts)	3	Bones largely dry, but retaining some grease	n/a
(13pts)	4	Dry bone	n/a

Note: n/a, no modifications.

Several of the observed differences may be attributed to the insect colonization pattern that seemed different in our study compared to Keough et al. [12], possibly linked to the different environments (forest vs open field). For instance, we observed larval masses in the anal region along with those in the head/neck orifices, while their study only noted maggot colonization in the head/neck region and in blisters of the trunk. In addition, maggot masses seemed to be present earlier and were more extensive in our study. This affected the decomposition pattern and rate in a way that was apparently not the case in the study by Keough et al. [12]. For instance, our carcass decomposition was strongly imbalanced between body regions and even caused scoring discrepancies within them. Further examples are that the front (cranial) part of the trunk sometimes exhibited skeletonization already while the rear (caudal) part was still in early decomposition and that the forelimbs decomposed quicker than the hind limbs. Furthermore, the maggot masses sometimes prevented visual examination of the decomposition, for example, whether the bone was exposed in more or less than half the area scored, and the masses further caused overlaps of some scores, for example, from

fresh to skeletonized directly. These observations were not made by Keough et al. [12] in the South African sample, but also noted by Pittner and colleagues in northern Germany [5].

The only two pigs that did not reach the maximum TBS during the study were P2 and P4, due to remaining soft tissue on the head/neck and trunk, respectively. Both these pigs were caged, but P4 was exposed to direct sunlight and P2 was placed in the shade. While the sun desiccated the soft tissue, cages had no *direct* effect on decomposition, but rather slow it down by restricting access for scavengers [6, 16, 57, 58]. However, our small sample does not allow any clear conclusions to be drawn about the cause of the remaining soft tissue in the two pigs.

The discrepancies between our study and the South African study [12] are not surprising since the experiments were conducted in different geographical regions (South Africa vs Switzerland), climates (humid subtropical Cfa vs humid temperate Cfb) and weather conditions (dry and warm vs rainy and warm). In general, our results support the inclusion of pig-specific amendments on the original TBS version by Megyesi et al. [2]. However, as others before have stated, even the porcine methods might not be applicable to all climates and environments

TABLE 3 Porcine partial body scoring for the trunk by Keough et al. [12] and our suggested modifications for future applications in temperate forest environments.

		Keough et al. (2017)	This study
A. Fresh			
(1 pt)	1	Fresh, no discoloration – slight lividity (pink)	n/a
B. Early decomposition			
(2pts)	1	Skin appears shiny/glossy with early bloating and may show purple-black discoloration over abdominal area	Skin might appear shiny/glossy, early bloating, localized gray-green discoloration over abdominal area
(3pts)	2	Gray-purple to green discoloration: some flesh still relatively fresh; marbling of abdomen with maximum bloat	Gray-green discoloration, some flesh still relatively fresh, marbling of abdomen
(4pts)	3	Purple-black discoloration and purging of decompositional fluids; skin slippage with maggot-filled blisters present; hair loss	Dark-green to purple-black discoloration, possible maggot colonization of anus
(5pts)	4	Postbloating following release of the abdominal gases, with extensive skin slippage and drying out of blisters	Post-bloating following release of the abdominal gases, skin blisters, blisters possibly filled with maggots
C. Advanced decomposition			
(7pts)	1	Decomposition of tissue producing sagging of flesh; caving in of the abdominal cavity	n/a
(8pts)	2	Moist decomposition with bone exposure less than one half that of the area being scored	n/a
(9pts)	3	Mummification with bone exposure less than one half that of the area being scored	n/a
D. Skeletonization			
(10pts)	1	Bones with decomposed tissue, sometimes with body fluids and grease still present	n/a
(11pts)	2	Bones with desiccated or mummified tissue covering less than one half of the area being scored	n/a
(12pts)	3	Bones largely dry, but retaining some grease	n/a
(13pts)	4	Dry bone	n/a

Note: n/a, no modifications.

[29]. Therefore, we consider our observed deviations important enough to justify a revised version of the porcine TBS tables, adapted for pig decomposition in a temperate climate. With this revised system, pig decomposition in Central Europe can be scored more appropriately and give information relevant to human decomposition and forensic practice where no prospective human taphonomy research is feasible.

Our study demonstrates that TBS tables work sufficiently for a broad estimate but that region-specific amendments should be considered.

During our study, we noted issues related to the original method proposed by Megyesi et al. [2]. For instance, vertebrate scavenging is not accounted for, despite scavengers being able to considerably accelerate the decomposition rate and therefore influence ADD estimation and, in turn, PMI estimation [59–61]. Similar concerns have been noted before [43]. They are further reinforced by our findings of a red fox causing an increase in TBS when removing the remaining mummified skin. Moreover, rainfall rehydrated desiccated soft tissues, leading to a lower TBS than would actually be the case. For instance, before rainfall, the partly skeletonized trunk would appear with mummified tissue remains and be scored with 11 points (“bones with desiccated or mummified tissue ...”), while the same

carcass would be assigned 10 points after rainfall rehydrated the tissue (“bones with decomposed tissue ...”) – going back in the scores. Consequently, this would introduce uncertainty in PMI estimations, potentially misleading forensic investigations. This challenge was also raised in previous studies [19, 28, 59].

In general, we do not think that the range of carcass weight in our study (49–51 kg) caused a notable variance in decomposition. Nevertheless, smaller carcasses were shown to decompose more quickly [62] and a carcass mass of 50–100 kg is recommended for forensic taphonomy research [63]. In addition, a Swiss study has calculated an average adult body weight of 66.4 kg for women and 81.5 kg for men [64]. Therefore, the difference in mass between our comparatively light cadavers and routine cases probably represents an uncertainty in the application to forensic casework.

4.2 | Intra-/inter-observer agreement

The very good agreement found between raters scoring TBS in our study supports previously published works [19, 36, 65]. They have also shown that agreements were highest for the Keough et al. [12]

TABLE 4 Porcine partial body scoring for the limbs by Keough et al. [12] and our suggested modifications for future applications in temperate forest environments.

		Keough et al. (2017)	This study
A. Fresh			
(1 pt)	1	Fresh, no discoloration – slight lividity (pink) with rigor present	n/a
B. Early decomposition			
(2pts)	1	Pink-white appearance with bloating of proximal parts of limbs	Pink-white appearance with bloating of proximal parts of limbs, marbling
(3pts)	2	Gray to green discoloration: marbling and shiny appearance of skin; some flesh still relatively fresh; skin slippage and hair loss	Gray to green discoloration, bloating of the entire limb
(4pts)	3	Discoloration and/or brownish shades particularly at edges, drying of skin (starting distal to proximal)	n/a
(5pts)	4	Brown to black discoloration, skin having a leathery appearance	Dark-green to black discoloration, skin slippage, loss of hooves
C. Advanced decomposition			
(7pts)	1	Moist decomposition with bone exposure less than one half that of the area being scored	n/a
(8pts)	2	Mummification with bone exposure less than one half that of the area being scored	n/a
D. Skeletonization			
(10pts)	1	Bone exposure over one half the area being scored, some decomposed tissue and body fluids remaining	n/a
(11pts)	2	Bones largely dry, but retaining some grease	Bones with desiccated or mummified tissue covering less than one half of the area being scored
(12pts)	3	Dry bone	Bones largely dry, but retaining some grease
(13pts)	4		Dry bone

Note: n/a, no modifications.

TABLE 5 Results of the ANOVA to identify biases between ADD and the presence of direct sunlight and cages at selected TBS values according to Keough et al. [12].

TBS	Factor	df	Sum of squares	Mean squares	F-ratio	p-Value
6	Sun	1	38.163	38.163	76.327	0.013
	Cage	1	0.000	0.000	0.000	1.000
	Residuals	6	12753.6			
13	Sun	1	666.125	666.125	6.846	0.232
	Cage	1	1023.12	1023.12	10.515	0.190
	Residuals	4	54967.3			
23	Sun	1	477.864	477.864	1.737	0.413
	Cage	1	47.730	47.730	0.017	0.917
	Residuals	5	253115.3			
25	Sun	1	519.721	519.721	0.473	0.617
	Cage	1	1040.6	1040.6	0.946	0.509
	Residuals	5	483806.4			
31	Sun	1	379.765	379.765	2.685	0.243
	Cage	1	153135.3	153135.3	1.083	0.407
	Residuals	5	5534144.3			

Note: Bold value is significant at $p \leq 0.05$.

Abbreviation: df, degrees of freedom.

version when scoring pigs, compared to the original Megyesi et al. [2] scoring method for humans, and that photographic rating returned higher inter-observer agreement values compared to real-life

observations, regardless of the system applied [19]. We noted a particular issue with the scoring from photographs that could affect the inter-observer agreement negatively. Scoring the glossy/shiny skin

TABLE 6 The values obtained when applying the Keough et al. [12] TBS scoring model to our sample. Intra- and inter-observer agreement analysis was interpreted following Cohen [52] for the weighted Kappa analysis and Koo [54] for the intraclass correlation coefficient (ICC), respectively.

Pig	Intra-observer			Inter-observer		
	Weighted kappa	Sig.	Agreement	ICC	Sig.	Agreement
P1	0.886	0.000	Almost perfect	0.997	0.000	Excellent
P2	0.891	0.000	Almost perfect	0.994	0.000	Excellent
P3	0.871	0.000	Almost perfect	0.996	0.000	Excellent
P4	0.764	0.000	Substantial	0.988	0.000	Excellent
P5	0.920	0.000	Almost perfect	0.997	0.000	Excellent
P6	0.940	0.000	Almost perfect	0.998	0.000	Excellent
Total	0.912	0.000	Almost perfect	0.995	0.000	Excellent

Note: All values are significant at $\alpha \leq 0.05$.

variable from photographs was challenging, in particular when there was no camera flash used or no direct sunlight caused reflections, similar to previous descriptions [19]. Rainwater can have the opposite effect and cause a shiny/glossy skin surface when it would be matt. In photographs, it is difficult to distinguish between shiny surfaces due to decomposition processes and those due to rainwater; this challenge could be solved by in situ observations. Nevertheless, we changed the scoring text to “skin might appear shiny/glossy” in our amended TBS tables.

The intra-observer agreement conducted by rater 1 was in the highest category for all pigs with the exception of P4, which was the only pig where a large flap of desiccated skin covered the trunk until the end of the experiment. Rater 1 had the least experience, but scoring differences due to level of education were non-significant in previous studies on photographs of human cadavers [35, 65]. Therefore, this slightly lower agreement for P4 may be due to rater 1 being the only in situ examiner of the remains and rating all the photographs available, thus, being aware of the multiple soft tissue rehydration cycles. This potential source of bias is especially relevant for future experimental work with retrospective scoring, but likely neglectable in forensic cases with only a single cross-sectional scoring event.

4.3 | Future work

In order to better understand driving variables for decomposition in the studied environment, comparable experiments with quantified sunlight exposure, humidity measurements and various seasons are required [43]. Our study shows the potential to further investigate decomposition differences between sun-exposed and shaded carcasses and it would be interesting to re-evaluate a similar setup in summer again to control for the unusually high rainfall during our experiment (about 27% above the average of the last 10 years). The effect of clothing on TBS evaluation is another topic that requires attention, especially since most forensic cases comprise clothed cadavers [17, 49, 63, 64, 66]. Moreover, a retrospective survey of forensic casework could inform about human decomposition and evaluate

experimental findings. Furthermore, we recommend consideration of alternative decomposition scoring methods, for instance, an independent trait system [43, 55]. In addition, as others before [43, 55], we suggest to include invertebrate and vertebrate activity as factors in the scoring systems.

5 | CONCLUSION

Experimental taphonomy research on exposed human cadavers is currently not feasible in Central Europe, thus, we propose a modified approach to follow in future porcine decomposition studies. Our work will help to improve the regional applicability of the TBS rating in order to inform forensic practice, specifically in a temperate forest environment in summer. We propose further studies in comparable environments but during different seasons and advocate to focus on differential decomposition between sun-exposed and shaded carcasses. Finally, we found that TBS rating from photographs bears some challenges such as the appearance of shiny skin, soft tissue rehydration, and maggot masses. Nevertheless, scoring pigs from photographs returns a high agreement among observers of comparable experience when using the Keough et al. [12] scoring system.

ACKNOWLEDGMENTS

We would like to thank the numerous helpers who kindly provided their support during the fieldwork, enduring physical and odorous adventures. Special thanks for that go to Giovanna Ceppi. We also want to thank the following institutions and persons for their valuable guidance, collaboration, and/or permits granted, all necessary for the successful conduction of the decomposition experiment and creation of this resulting publication: The Department of Clinical Veterinary Science of the University of Bern; the Veterinary Office of the Canton of Bern; the Staatsforstbetrieb Bern; Edward Mitchell of the Laboratory of Soil Biodiversity at the University of Neuchâtel; and Martin Gossner of the Swiss Federal Institute for Forest, Snow, and Landscape Research (WSL). We would also like to thank Oliver Indra for his support regarding the meteorological data and Sandra Braun for reviewing our manuscript. Open access funding provided by Universitat Bern.

CONFLICT OF INTEREST STATEMENT

The authors have no conflicts of interest to disclose.

ORCID

Lara Indra  <https://orcid.org/0000-0001-6644-2133>

Stephanie Giles  <https://orcid.org/0000-0002-6669-2463>

Clara Alfsdotter  <https://orcid.org/0000-0002-0181-4458>

David Errickson  <https://orcid.org/0000-0002-9792-671X>

Sandra Lösch  <https://orcid.org/0000-0003-3442-9764>

REFERENCES

- Galloway A, Birkby WH, Jones A, Henry TE, Parks BO. Decay rates of human remains in an arid environment. *J Forensic Sci.* 1989;34(3):607–16. <https://doi.org/10.1520/JFS12680J>
- Megyesi MS, Nawrocki S, Haskell NH. Using accumulated degree-days to estimate the postmortem interval from decomposed human remains. *J Forensic Sci.* 2005;50(3):618–26. <https://doi.org/10.1520/JFS2004017>
- Feddern N, Mitchell EAD, Amendt J, Szelez I, Seppey CVW. Decomposition and insect colonization patterns of pig cadavers lying on forest soil and suspended above ground. *Forensic Sci Med Pathol.* 2019;15(3):342–51. <https://doi.org/10.1007/s12024-019-00121-6>
- Szelez I, Feddern N, Seppey CVW, Amendt J, Mitchell EAD. The importance of *Saprinus semistriatus* (Coleoptera: Histeridae) for estimating the minimum post-mortem interval. *Legal Med.* 2018;30:21–7. <https://doi.org/10.1016/j.legalmed.2017.10.011>
- Pittner S, Bugelli V, Weitgasser K, Zissler A, Sanit S, Lutz L, et al. A field study to evaluate PMI estimation methods for advanced decomposition stages. *Int J Legal Med.* 2020;134(4):1361–73. <https://doi.org/10.1007/s00414-020-02278-0>
- Thümmel L, Lutz L, Geissenberger J, Pittner S, Heimer J, Amendt J. Decomposition and insect succession of pig cadavers in tents versus outdoors – a preliminary study. *Forensic Sci Int.* 2023;346:111640. <https://doi.org/10.1016/j.forsciint.2023.111640>
- Geissenberger J, Amendt J, Klampfer J, Thuemmel L, Jakob L, Monticelli FC, et al. Morphological changes and protein degradation during the decomposition process of pig cadavers placed outdoors or in tents—a pilot study. *Forensic Sci Med Pathol.* 2023. <https://doi.org/10.1007/s12024-023-00632-3>
- Szelez I, Fournier B, Seppey CV, Amendt J, Mitchell EA. Can soil testate amoebae be used for estimating the time since death? A field experiment in a deciduous forest. *Forensic Sci Int.* 2014;236:90–8. <https://doi.org/10.1016/j.forsciint.2013.12.030>
- Szelez I, Sorge F, Seppey CVW, Mulot M, Steel H, Neilson R, et al. Effects of decomposing cadavers on soil nematode communities over a one-year period. *Soil Biol Biochem.* 2016;103:405–16. <https://doi.org/10.1016/j.soilbio.2016.09.011>
- Seppey CV, Fournier B, Szelez I, Singer D, Mitchell EA, Lara E. Response of forest soil euglyphid testate amoebae (Rhizaria: Cercozoa) to pig cadavers assessed by high-throughput sequencing. *Int J Legal Med.* 2016;130(2):551–62. <https://doi.org/10.1007/s00414-015-1149-7>
- Szelez I, Koenig I, Seppey CVW, Le Bayon R-C, Mitchell EAD. Soil chemistry changes beneath decomposing cadavers over a one-year period. *Forensic Sci Int.* 2018;286:155–65. <https://doi.org/10.1016/j.forsciint.2018.02.031>
- Keough N, Myburgh J, Steyn M. Scoring of decomposition: a proposed amendment to the method when using a pig model for human studies. *J Forensic Sci.* 2017;62(4):986–93. <https://doi.org/10.1111/1556-4029.13390>
- Pittner S, Bugelli V, Benbow ME, Ehrenfellner B, Zissler A, Campobasso CP, et al. The applicability of forensic time since death estimation methods for buried bodies in advanced decomposition stages. *PLoS One.* 2020;15(12):e0243395. <https://doi.org/10.1371/journal.pone.0243395>
- Pecsi EL, Bronchti G, Crispino F, Forbes SL. Perspectives on the establishment of a Canadian human taphonomic facility: the experience of REST(ES). *Forensic Sci Int Synerg.* 2020;2:287–92. <https://doi.org/10.1016/j.fsisyn.2020.09.001>
- Varlet V, Joye C, Forbes SL, Grabherr S. Revolution in death sciences: body farms and taphonomics blooming. A review investigating the advantages, ethical and legal aspects in a Swiss context. *Int J Legal Med.* 2020;134(5):1875–95. <https://doi.org/10.1007/s00414-020-02272-6>
- Matuszewski S, Hall MJR, Moreau G, Schoenly KG, Tarone AM, Villet MH. Pigs vs people: the use of pigs as analogues for humans in forensic entomology and taphonomy research. *Int J Legal Med.* 2020;134(2):793–810. <https://doi.org/10.1007/s00414-019-02074-5>
- Miles KL, Finaughty DA, Gibbon VE. A review of experimental design in forensic taphonomy: moving towards forensic realism. *Forensic Sci Res.* 2020;5(4):249–59. <https://doi.org/10.1080/20961790.2020.1792631>
- Indra L, Lösch S, Errickson D, Finaughty D. Forensic experiments on animal scavenging: a systematic literature review on what we have and what we need. *Forensic Sci Int.* 2023;353:111862. <https://doi.org/10.1016/j.forsciint.2023.111862>
- Ribéreau-Gayon A, Rando C, Morgan RM, Carter DO. The suitability of visual taphonomic methods for digital photographs: an experimental approach with pig carcasses in a tropical climate. *Sci Justice.* 2018;58(3):167–76. <https://doi.org/10.1016/j.scijus.2017.12.001>
- Stokes KL, Forbes SL, Tibbett M. Human versus animal: contrasting decomposition dynamics of mammalian analogues in experimental taphonomy. *J Forensic Sci.* 2013;58(3):583–91. <https://doi.org/10.1111/1556-4029.12115>
- Dawson BM, Barton PS, Wallman JF. Contrasting insect activity and decomposition of pigs and humans in an Australian environment: a preliminary study. *Forensic Sci Int.* 2020;316:110515. <https://doi.org/10.1016/j.forsciint.2020.110515>
- Connor M, Baigent C, Hansen ES. Testing the use of pigs as human proxies in decomposition studies. *J Forensic Sci.* 2018;63(5):1350–5. <https://doi.org/10.1111/1556-4029.13727>
- Dautartas A, Kenyhercz MW, Vidoli GM, Meadows Jantz L, Mundorff A, Steadman DW. Differential decomposition among pig, rabbit, and human remains. *J Forensic Sci.* 2018;63(6):1673–83. <https://doi.org/10.1111/1556-4029.13784>
- Dawson BM, Wallman JF, Barton PS. How does mass loss compare with total body score when assessing decomposition of human and pig cadavers? *Forensic Sci Med Pathol.* 2022;18(3):343–51. <https://doi.org/10.1007/s12024-022-00481-6>
- DeBruyn JM, Hoeland KM, Taylor LS, Stevens JD, Moats MA, Bandopadhyay S, et al. Comparative decomposition of humans and pigs: soil biogeochemistry, microbial activity and metabolomic profiles. *Front Microbiol.* 2021;11:608856. <https://doi.org/10.3389/fmicb.2020.608856>
- Roberts LG, Dabbs GR. A taphonomic study exploring the differences in decomposition rate and manner between frozen and never frozen domestic pigs (*Sus scrofa*). *J Forensic Sci.* 2015;60(3):588–94. <https://doi.org/10.1111/1556-4029.12717>
- Sutherland A, Myburgh J, Steyn M, Becker PJ. The effect of body size on the rate of decomposition in a temperate region of South Africa. *Forensic Sci Int.* 2013;231(1–3):257–62. <https://doi.org/10.1016/j.forsciint.2013.05.035>
- Lynch-Aird J, Moffatt C, Simmons T. Decomposition rate and pattern in hanging pigs. *J Forensic Sci.* 2015;60(5):1155–63. <https://doi.org/10.1111/1556-4029.12796>
- Hill MA, Pokines JT. Comparative analysis of fetal pig decomposition processes in burials of variable depths and wrapping. *J Forensic Sci.* 2022;67(6):2192–202. <https://doi.org/10.1111/1556-4029.15120>

30. Probst C, Gethmann J, Amendt J, Lutz L, Teifke JP, Conraths FJ. Estimating the postmortem interval of wild boar carcasses. *Vet Sci*. 2020;7(1):6. <https://doi.org/10.3390/vetsci7010006>
31. Nolan AN, Maker G, Mead RJ, Bringans S, Speers SJ. Peptide analysis of mammalian decomposition fluid in relation to the post-mortem interval. *Forensic Sci Int*. 2020;311:110269. <https://doi.org/10.1016/j.forsciint.2020.110269>
32. Schultz JJ, Mitchell AT. Avian scavenging of small-sized pig carcasses in Central Florida: utilizing GIS to analyze site variables affecting skeletal dispersal. *J Forensic Sci*. 2018;63(4):1021–32. <https://doi.org/10.1111/1556-4029.13694>
33. Marhoff-Beard SJ, Forbes SL, Green H. The validation of 'universal' PMI methods for the estimation of time since death in temperate Australian climates. *Forensic Sci Int*. 2018;291:158–66. <https://doi.org/10.1016/j.forsciint.2018.08.022>
34. Forbes SL, Finaughty DA, Miles KL, Gibbon VE. Inaccuracy of accumulated degree day models for estimating terrestrial post-mortem intervals in Cape Town, South Africa. *Forensic Sci Int*. 2019;296:67–73. <https://doi.org/10.1016/j.forsciint.2019.01.008>
35. Dabbs GR, Connor M, Bytheway JA. Interobserver reliability of the total body score system for quantifying human decomposition. *J Forensic Sci*. 2016;61(2):445–51. <https://doi.org/10.1111/1556-4029.12962>
36. Dabbs GR, Bytheway JA, Connor M. Comparing the scoring of human decomposition from digital images to scoring using on-site observations. *J Forensic Sci*. 2017;62(5):1292–6. <https://doi.org/10.1111/1556-4029.12962>
37. Indra L, Lösch S. Forensic anthropology casework from Switzerland (Bern): Taphonomic implications for the future. *Forensic Sci Int Rep*. 2021;41 00222. <https://doi.org/10.1016/j.fsir.2021.100222>
38. Simmons T. Post-mortem interval estimation: an overview of techniques. In: Schotsmans EMJ, Marquez-Grant N, Forbes SL, editors. (Eds.)Taphonomy of human remains: forensic analysis of the dead and the depositional environment. Hoboken, NJ: Wiley & Sons Ltd; 2017. p. 134–42. <https://doi.org/10.1002/9781118953358.ch10>
39. Schultz JJ. Determining the forensic significance of skeletal remains. In: Dirkmaat DC, editor. (ed.)A companion to forensic anthropology. West Sussex, U.K.: John Wiley & Sons; 2012. p. 66–84.
40. Forbes SL, Nugent K. Dating of anthropological skeletal remains of forensic interest. In: Blau S, Ubelaker DH, editors. (Eds.)Handbook of forensic archaeology and anthropology. Walnut Creek, CA: Left Coast Press; 2009. p. 164–73.
41. Vass AA, Bass WM, Wolt JD, Ammons JT. Time since death determinations of human cadavers using soil solution. *J Forensic Sci*. 1992;37(5):1236–53. <https://doi.org/10.1520/JFS13311J>
42. Mann RW, Bass WM, Meadows L. Time since death and decomposition of the human body. Variables and observations in case and experimental field studies. *J Forensic Sci*. 1990;35(1):103–11. <https://doi.org/10.1520/JFS12806J>
43. Giles SB, Harrison K, Errickson D, Márquez-Grant N. The effect of seasonality on the application of accumulated degree-days to estimate the early post-mortem interval. *Forensic Sci Int*. 2020;315:110419. <https://doi.org/10.1016/j.forsciint.2020.110419>
44. Wescott DJ. Recent advances in forensic anthropology: decomposition research. *Forensic Sci Res*. 2018;3(4):327–42. <https://doi.org/10.1080/20961790.2018.1488571>
45. Kottke M, Grieser J, Beck C, Rudolf B, Rubel F. World map of the Köppen-Geiger climate classification updated. *Meteorol Z*. 2006;15(3):259–63. <https://doi.org/10.1127/0941-2948/2006/0130>
46. MeteoSchweiz. Messwerte: Bern/Zollikofen [Measurement values: Bern/Zollikofen]. Bern, Switzerland: Bundesamt für Meteorologie und Klimatologie Meteo Schweiz 2018 Accessed February 12, 2024. <https://www.meteoschweiz.admin.ch/home/messwerte.html?param=messwerte-lufttemperatur-10min&station=BER&chart=d y>
47. European Centre for Medium-Range Weather Forecasts (ECMWF). ERA5: fifth generation of ECMWF atmospheric reanalyses of the global climate. ECMWF reanalysis, v5. Reading, UK: ECMWF; 2023.
48. Swiss National Animal Protection Ordinance, SR 455.1, Kap.8 TSchV. 2008.
49. Spies MJ, Finaughty DA, Friedling LJ, Gibbon VE. The effect of clothing on decomposition and vertebrate scavengers in cooler months of the temperate southwestern cape, South Africa. *Forensic Sci Int*. 2020;3091 10197. <https://doi.org/10.1016/j.forsciint.2020.110197>
50. Perez AE, Haskell NH, Wells JD. Commonly used intercarcass distances appear to be sufficient to ensure independence of carrion insect succession pattern. *Ann Entomol Soc Am*. 2016;109(1):72–80. <https://doi.org/10.1093/aesa/sav102>
51. Dabbs GR. How should forensic anthropologists correct national weather service temperature data for use in estimating the post-mortem interval? *J Forensic Sci*. 2015;60(3):581–7. <https://doi.org/10.1111/1556-4029.12724>
52. Cohen J. Weighted kappa: nominal scale agreement provision for scaled disagreement or partial credit. *Psychol Bull*. 1968;70(4):213–20. <https://doi.org/10.1037/h0026256>
53. Landis JR, Koch GG. The measurement of observer agreement for categorical data. *Biometrics*. 1977;33(1):159–74. <https://doi.org/10.2307/2529310>
54. Koo TK, Li MY. A guideline of selecting and reporting intraclass correlation coefficients for reliability research. *J Chiropr Med*. 2016;15(2):155–63. <https://doi.org/10.1016/j.jcm.2016.02.012>
55. Giles SB, Errickson D, Márquez-Grant N. Decomposition variability between the scene and autopsy examination and implications for post-mortem interval estimations. *J Forensic Leg Med*. 2022;851 02292. <https://doi.org/10.1016/j.jflm.2021.102292>
56. Gleiber DS, Meckel LA, McDaniel CP, Siegert C, Pyle J, Wescott DJ. (Eds.)Accumulated decomposition score (ADS): an alternative method to TBS for quantifying gross morphological changes associated with decomposition. Proceedings of the 69th annual scientific meeting of the American Academy of forensic sciences. New Orleans, LA. Colorado Springs, CO: American Academy of Forensic Sciences; 2017.
57. Tobajas J, Descalzo E, Ferreras P, Mateo R, Margalida A. Effects on carrion consumption in a mammalian scavenger community when dominant species are excluded. *Mamm Biol*. 2021;101(6):851–9. <https://doi.org/10.1007/s42991-021-00163-w>
58. Olson ZH, Beasley JC, DeVault TL, Rhodes OE. Scavenger community response to the removal of a dominant scavenger. *Oikos*. 2012;121(1):77–84. <https://doi.org/10.1111/j.1600-0706.2011.19771.x>
59. Suckling JK, Spradley MK, Godde K. A longitudinal study on human outdoor decomposition in Central Texas. *J Forensic Sci*. 2015;61(1):19–25. <https://doi.org/10.1111/1556-4029.12892>
60. Séguin K, Durand-Guevin A, Lavalée C, Quimet F, Maisonhaute JE, Watson CJ, et al. The taphonomic impact of scavenger guilds in southern Quebec during summer and fall in two distinct habitats. *J Forensic Sci*. 2021;67(2):460–70. <https://doi.org/10.1111/1556-4029.14929>
61. Forbes SL, Samson C, Watson CJ. Seasonal impact of scavenger guilds as taphonomic agents in central and northern Ontario, Canada. *J Forensic Sci*. 2022;67(6):2203–17. <https://doi.org/10.1111/1556-4029.15122>
62. Komar D, Beattie O. Effects of carcass size on decay rates of shade and sun exposed carrion. *J Can Soc Forensic Sci*. 1998;31(1):35–43. <https://doi.org/10.1080/00085030.1998.10757107>
63. Simmons T, Adlam R, Moffatt C. Debugging decomposition data – comparative taphonomic studies and the influence of insects and carcass size on decomposition rate. *J Forensic Sci*. 2010;55(1):8–13. <https://doi.org/10.1111/j.1556-4029.2009.01206.x>
64. Marques-Vidal P, Pecoud A, Hayoz D, Paccaud F, Mooser V, Waeber G, et al. Prevalence of normal weight obesity in Switzerland: effect

- of various definitions. *Eur J Nutr.* 2008;47(5):251–7. <https://doi.org/10.1007/s00394-008-0719-6>
65. Nawrocka M, Fratczak K, Matuszewski S. Inter-rater reliability of total body score – a scale for quantification of corpse decomposition. *J Forensic Sci.* 2016;61(3):798–802. <https://doi.org/10.1111/1556-4029.13105>
66. Ueland M, Forbes SL, Stuart BH. Understanding clothed buried remains: the analysis of decomposition fluids and their influence on clothing in model burial environments. *Forensic Sci Med Pathol.* 2019;15(1):3–12. <https://doi.org/10.1007/s12024-018-0073-9>

How to cite this article: Indra L, Giles S, Alfsdotter C, Errickson D, Lösch S. Evaluation of porcine decomposition and total body score (TBS) in a central European temperate forest. *J Forensic Sci.* 2024;69:784–97. <https://doi.org/10.1111/1556-4029.15497>

Evaluation of porcine decomposition and total body score (TBS) in a central European temperate forest

Indra, Lara

2024-02-26

Attribution-NonCommercial 4.0 International

Indra L, Giles S, Alfsdotter C, et al., (2024) Evaluation of porcine decomposition and total body score (TBS) in a central European temperate forest. *Journal of forensic sciences*. Volume 69, Issue 3, May 2024, pp. 784-797

<https://doi.org/10.1111/1556-4029.15497>

Downloaded from CERES Research Repository, Cranfield University