

Spanish Civil War: the recovery and identification of combatants

Lourdes Herrasti ⁽¹⁾, Nicholas Márquez-Grant ⁽²⁾
and Francisco Etxeberria ^(1, 3)

(1) Departamento de Antropología. Sociedad de Ciencias Aranzadi, Donostia-San Sebastián, Spain

(2) Cranfield Forensic Institute, Cranfield University, Defence Academy of the United Kingdom, UK

(3) Facultad de Medicina y Enfermería, Universidad del País Vasco, Spain

Abstract

In the context of exhumations of individuals who died during the Spanish Civil War (1936-1939), since the year 2000, over 780 mass graves have been excavated using archaeological methodology and following forensic protocols. Most of the recovered more than 9600 bodies have tended to be from the Republican civil population, the majority having been executed extrajudicially. However, a number of exhumations relate to the remains of soldiers who died in combat. In fact, approximately 100 individual or mass graves have been investigated and exhumed, containing the remains of combatants. These burials tend to be in the same location where they fell, usually in the front line, or close to the field hospitals where they went after being wounded initially. During the recovery of the human remains, a number of artefacts related to the uniform as well as personal effects have been found. An interdisciplinary approach from archaeology, anthropology, genetics, history and other disciplines has enabled the identification of some of these combatants.

The aim of this paper is to present the data obtained from these combatants and highlight the work undertaken in Spain, and the efforts by scientists to exhume, identify and return the remains to relatives where possible.

Keywords: Spanish Civil War, Forensic Archaeology, Forensic Anthropology, Mass Graves, combatants, human remains.

Introduction

Forensic archaeology and forensic (physical) anthropology have shown their potential in the recovery of the remains of soldiers who fell during combat throughout the 20th and 21st centuries [1-3]. In Spain, one of the organisations that has worked intensively in the recovery and identification of conflict casualties from Prehistory to more recent times, has been the Sociedad de Ciencias Aranzadi (SCA) or Aranzadi Science Society, created in 1947 [4]. The team of forensic archaeologists, anthropologists and other specialists (e.g. logistics, mountaineering) from SCA, led by two of the authors of this paper (LH, FE) has participated in investigating contexts of violence in sites dating to Prehistory to the present day. These archaeological sites have better prepared the scientists for the excavation of mass graves and analysis of peri-mortem trauma in more modern contexts. Examples of this experience include exhumations of soldiers from the Spanish War of Independence or 'Peninsular War' (1808-1814) where Spain, Britain and Portugal were allies against the Napoleonic army. Two examples, one from El Carrascal (Navarra) and the other from a cemetery near the convent of Clara de Tolosa (Gipuzkoa), revealed a number of French soldiers buried in mass graves, some of whom evidenced skeletal lesions consistent with lead projectiles, as well as surgical intervention in the latter example [5-7]. Other examples of the historical mass graves investigated include that in the village of Ocio (Álava) where the remains of 12 soldiers who died in 1822 were recovered [8].

Amongst some of the forensic and humanitarian investigations undertaken by this society in recent years, was the collaboration with the International Committee for the Red Cross (ICRC) in 2017 to exhume and identify Argentinian soldiers who died in the Falkland Islands (Islas Malvinas) in 1982.¹

However, the focus of this paper is the Spanish Civil War (1936-1939), an area where the society has since the year 2000, exhumed thousands of victims from hundreds of mass graves throughout Spain. Although a considerable amount has been written on the history of the Spanish Civil War [9], and much archaeological work has been done on the Civil War's infrastructure, the trenches, and material culture in general [10-12], this paper focuses on the deceased. In particular, the aim is to provide information on the forensic archaeological and anthropological work undertaken to recover and identify the combatants who died in this conflict.

This paper will first examine the wider Spanish context in which these exhumations have taken place, and will show, by means of case studies, the process from search through to excavation, recovery and identification of combatants.

Spanish Civil War exhumations

The Spanish Civil War started in July 1936 and ended in April 1939 [13]. It has been estimated that between 150,000-200,000 people died in combat, in addition to the 150,000 victims who had died in acts of repression [14-16].

¹ <https://www.icrc.org/en/document/malvinas-falkland-islands-giving-dead-back-their-names> (accessed October 2020).

In the last two decades there has been a great development in the forensic archaeology and anthropology of the Spanish Civil War [17]. Much of this work has focused on the recovery and identification of the civilian population who were executed and buried in clandestine graves in fields, pits, cemeteries amongst other locations [18-19].

In fact, the recovery of human remains of the Civil War took place during the actual conflict and during the Francoist dictatorship, especially in the 1940s with the "Causa General", when those who fell for General Francisco Franco had their bodies exhumed. In 1958, the Mausoleum from the Valle of the Fallen (Valle de los Caídos) was constructed, where the remains of over 30,000 people were buried, including also the bodies of Republican soldiers [20]. The latter is one of the reasons why the civilian population buried in clandestine graves have been the focus of most of the exhumations carried out in Spain. By contrast, the exhumations of the Republican repressed civil population did not start until 1978 primarily by the families, during the period of democratic transition, before being interrupted by the coup d'état in 1981 [19]. In 1996 the recovery of the remains of Spanish soldiers as part of the Blue Division (División Azul) who perished in the eastern front during the Second World War was initiated and still continues today².

The actual process of exhuming individuals from the Spanish Civil War following scientific methodology (archaeology, anthropology, forensic science) started in the year 2000 [18-19]. In October that year, an archaeologist, Julio Vidal, and an anthropologist, Encina Prada, requested the collaboration of SCA, in particular that of Francisco Etxeberria, forensic pathologist, and Lourdes Herrasti, archaeologist³. This exhumation came at the request of a grandson from one of the deceased. The grave was located in Priaranza del Bierzo (León), and comprised a team which followed archaeological, forensic pathology and anthropological methodology to recovery and identify the deceased; it was thus, the first scientific exhumation of a mass grave of the civilian population executed during the Spanish Civil War (1936-1939). The human remains and associated artefacts of a total of thirteen male individuals between the ages of 25 and 45 years were recovered⁴. Since then and up to the end of 2019, more than 780 graves have been exhumed throughout Spain, with the recovery of more than 9,600 victims of the repression. Approximately 89% of these would correspond to civilian Republicans⁵.

Of all the graves exhumed, 100 correspond to the burials of combatants, in which a total of 530 individuals have been recovered. Many of them are individual burials or superficial findings of skeletal remains; but around 400 combatants have been recovered from war hospital cemeteries. This paper addresses the recovery and identification of some of those missing combatants.

² https://www.abc.es/historia/abci-division-azul-regreso-andrajosos-espanoles-terrorizaron-tanques-stalin-iigm-202010131103_noticia.html (accessed October 2020)

³ Archaeologists M^aLuz González and Venancio Carlón also participated in this exhumation

⁴ <https://memoriahistorica.org.es/wp-content/uploads/2015/02/Informe-forense-acerca-de-los-trece-de-Priaranza1.pdf> (accessed October 2020)

⁵ At the time of writing a government publication came out that provides a summary of the last 20 years of work in Spain.

https://www.mpr.gob.es/servicios/publicaciones/Documents/Exhumaciones_Guerra_Civil_accesible_BAJA.pdf (accessed December 2020)

The graves of combatants

The search for soldiers missing in action is one of the objectives in the archaeology of conflict [21]. With this objective in mind, archaeology is used to search, locate, document, interpret, and recover the war dead from a variety of locations, contexts and from different time periods.

During the Spanish Civil War, it was the local residents who initially buried the bodies of the dead combatants in a place near where they had been found; or in nearby cemeteries. This was the case of a confrontation in Mount Bizkargi in the north of Spain, where the corpses were transported some miles away in successive waves to the Muxika cemetery. Likewise, the bodies of the war dead from the battle of Villarreal (Araba) were taken to the Legutio cemetery. This situation was repeated for other battles throughout the Spanish geography.

The removal of the corpses and cleaning work constituted a necessary hygienic and sanitary measure, but it also tried to prevent animals, both wild and domestic, from scavenging the bodies left on the surface⁶. José de Arteche, a write of the time, described the removal of bodies by a team of ´shovel and pick soldiers´ on Mount Sabigain (Bizkaia) [22]. On many occasions, the recovery of the corpses was carried out a few days after the battle, so the bodies were still recognisable and their names could be identified at the temporary burial site on a cross which served as a grave marker. At times, however, several bodies buried together within the same grave. Those undertaking the burial, used all kinds of natural and artificial depressions too to avoid having to dig a grave. Examples of these were ditches, trenches and bomb craters, which had the advantage of being in the same battlefield where the combatant had died. It was thus practical to deposit the bodies into these features and structures and cover the area later with soil, resulting in temporary makeshift burials. As González-Ruibal puts it⁷, the bodies that lay in trenches were often the result of artillery fire or, alternatively, when occupied by enemy forces, these were used also as a burial ground. In addition, caves, chasms and wells were also used as deposition sites. These contexts have their own challenges for archaeological recoveries today and require a highly and multiple skilled team [23].

Search, excavation, recovery, identification and reburial

The location of the graves of combatants is closely linked to the evolution of the war and the position of the front lines. The following map (Figure 1) shows the location of the graves where excavations have been undertaken to recover the remains of those killed in battle. Figure 1 also shows the situation of hospitals and their associated cemeteries where fatally wounded soldiers would have been buried.

⁶ <https://www.icrc.org/es/doc/resources/documents/treaty/treaty-gc-1-5tdkna.htm> (accessed October 2020)

⁷ <http://guerraenlauniversidad.blogspot.com/2014/10/una-trinchera-una-tumba.html> (accessed October 2020)

Figure 1. Map showing the location of Spanish Civil War (1936-1939) combatant graves that have been exhumed to date.

These exhumations of combatants are distributed in three large geographical areas (see largest circles in Figure 1) which correspond to the war fronts:

1. The Northern Front, located in the northern part of the Iberian Peninsula, and in particular involving primarily the regions of the Basque Country, Cantabria and Asturias. Fighting here took place between August 1936 and November 1937.
2. The Ebro Valley, in the northeast-east of Spain comprising the regions of Catalonia, and the provinces of Teruel (Aragon) and Castelló (Valencia). This front is where the bloodiest battles took place between the months of July to November 1938 and the first months of 1939.
3. The area around Madrid, especially during the capital's siege between October 1936 and March 1939. There have only been a few exhumations carried out here.

Most of the archaeological interventions have been carried out following chance finds or through metal detectorists searching for objects which have ultimately been associated to the Civil War; for example when uncovering a holster or a canteen associated with human remains. Human remains from the Spanish Civil War are well beyond the 25 year time frame for medico-legal cases in the country, and therefore the police at present are not involved as it is not a judicial case (although with exceptions) [24-25]. For example, the discovery of disarticulated surface human remains under an overhanging rock in Txaldataxur II, in northern Spain⁸ by SCA, found a number of items that helped with dating the remains. In the abdominal area, a series of objects were recovered, including a canteen, an Astra 300 pistol with its leather holster, an English-made whistle of the Acme brand (Thunderer model), a lighter, ammunition and an identification disc with the number 4994.

In the area surrounding the city of Bilbao the fighting was very intense and a peripheral line of defence constructions, bunkers and machine gun nests, known as the "Iron Belt" (Cinturón de Hierro⁹) was established. The attack and advance of the Francoist troops intensified in April 1937, when fighting took place in the mountains around Bilbao. In these mountains, several burials of combatants have been located, for example around Ganzabal, Lemoatx and Larrabetzu (Figure 1). At Lemoatx, for example, the exhumation in 2014¹⁰ by a team of archaeologists and anthropologists recovered a body at the base of a tree, possibly in the same position in which the soldier died as a result of blast injury. From historical documentation it is known that his death probably occurred during the days of intense artillery attack between the 3rd and 5th of June 1937. The degree of preservation of the skeleton varied, since the upper half of the body was incomplete and weathered, but the lower half was in better condition. Associated to these remains, the equipment recovered included straps and two complete rubber holsters, a leather belt with a rectangular plate-buckle with the

⁸ <http://www.aranzadi.eus/antropologia-fisica/aranzadi-ha-exhumado-los-restos-de-un-combatiente-hallados-en-el-monte-txaldataxur-de-donostia> (accessed October 2020).

⁹ <https://www.cinturondehierro.net/es-es/> (accessed October 2020).

¹⁰ <https://aricomemoriaaragonesa.files.wordpress.com/2009/03/informe-de-exhumacion-de-un-combatiente-en-lemoatx-2014-aranzadi.pdf> (accessed October 2020)

Basque Government coat of arms, leather footwear, as well as a set of objects that could be stored in a backpack including espadrilles, a fountain pen, two razor blades, two brass spoons and a hand grenade. However, the most significant item was a link chain bracelet on the left wrist. From this bracelet hung a metal disk with the number 72865 engraved (Figure 2). After consulting in the Basque National Archive in Bilbao the list of payrolls of the different battalions, it was discovered that the number corresponded to a young adult male with the initials HRB, who belonged to the Socialist Battalion No. 28 of Barakaldo (Bizkaia) [26].



Figure 2. Bracelet with identification disc number 72865. Lemoatx (Bizkaia).

Examples of small mass graves or common graves are that of found in the vicinity of San Antolín (Lemoa, Bizkaia) with three combatants, or that of Ziardamendi¹¹, where four fallen soldiers were buried. In the latter case, the bodies were buried in a rectangular pit, arranged orderly with the head at each corner and the lower extremities in the centre. Two individuals have been identified through historical research¹², as the date of death was known to be 25th September 25 1936. This has facilitated the identification through searching relatives and carrying out genetic testing.

Examples within natural cavities and where the bodies of combatants were disposed by the local population (e.g. the grandfather of the person who informed the scientific team), the remains of two combatants were found in the Kutzetxiki chasm (Arrasate, Gipuzkoa). For the most complete body, located at the entrance ramp, the forensic anthropology analysis helped in the estimation of age-at-death, sex, stature and found several injuries from a firearm projectile to the right parietal (skull) and to the ninth thoracic vertebra (T9), the latter evidencing a perforation with loss of bone with a diameter of 8 mm (Figure 3). There are many other similar examples of concealment of bodies in natural cavities in the rock, pits, shafts, etc. [23].

¹¹ <https://docplayer.es/96672208-Informe-historico-preliminar-de-la-fosa-exhumada-en-ziardamendi-elgoibar-gipuzkoa-jimi-jimenez.html> (accessed October 2020)

¹² <https://www.noticiasdegipuzkoa.eus/actualidad/sociedad/2014/02/09/identifican-cuatro-gudaris-ziardamendi/311282.html> (accessed October 2020)

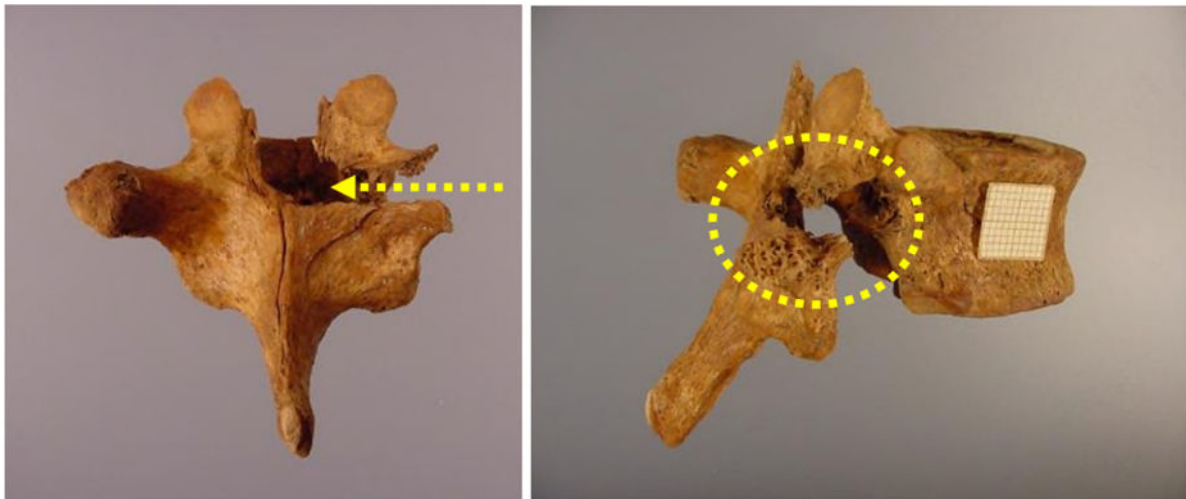


Figure 3. Thoracic vertebra with perforating injury as a result of the passage of a firearm projectile. Kurtzetxiki (Gipuzkoa).

With regard to use of trenches as a favourable place to dispose of the bodies, one case investigated by SCA can be mentioned here. This relates to the exhumation of three combatants in a trench in Zelaietaburu (Etxebarria, Bizkaia), who died in the first days of April 1937¹³. The informants mentioned that the trench line had been used to bury three soldiers. These individuals were found arranged in a row in a supine position. The skeletal remains were in a poor state of preservation due to the humidity and the action of the roots of the tree cover and this limited the anthropological analysis. Nevertheless, a removable upper arch dental prosthesis was found in one individual, whilst another individual had two yellow celluloid toothbrushes in the top right pocket of a jacket, one of the brand "Sanitas" and the other of English import with the words: "Made in England. Pure Brush" (Figure 4). The human remains of the other soldier (Individual 3) was in a poor state of preservation as they were found in the middle and deepest part of the trench.



Figure 4. Toothbrushes recovered from a trench in Zelaietaburu (Elgoibar, Gipuzkoa).

¹³ <http://www.todoslosnombres.org/content/noticias/pais-vasco-desenterrados-en-fosa-etxebarria-varios-gudaris-milicianos-fusilados> (accessed October 2020)

Aside from the battlefield, wounded soldiers who died in ar hospitals were buried in cemeteries nearby or associated with these facilities. The deceased were interred consecutively in open trenches that were gradually covered as interments occurred. This was the case, for example, in Solerás (Les Garrigues, Lleida, Catalonia), where an archaeological company exhumed a total of 150 individuals. Most of these individuals were Republican soldiers, but the remains also represented Francoist soldiers and several civilian residents killed as a result of a blast¹⁴. Other similar examples are the cemeteries of the Pernafeites de Miravet¹⁵ hospitals (Tarragona) and that of Uclés monastery (Cuenca).

Featured case studies from the Bizkaia region in northern Spain

Of all the exhumations of combatants carried out to date by SCA, there are two cases worth highlighting here which highlight the final aim of these investigations. The cases also cover the process of recovery of the remains, identification, return to the families, and remembrance [27].

Case study 1: village of Mendata

After the bombing and destruction of the town of Gernika by the aviation of the German Condor Legion and the Italian aviation on 26th April April 26 1937 [28], Basque nationalist troops of Otxandiano battalion had to withdraw. One of their soldiers was wounded and was taken to a village in Mendata (Bizkaia). The Francoist troops detained him and he was assassinated a short distance from the place where he was staying. The neighbours discovered what happened and buried the body next to an oak, which served as a point of reference for the villagers. The residents notified the relatives through the mediation of the village priest. The burial was marked with a cross with the image of the young man and they kept his memory with offerings of flowers every year around the anniversary of his death. In 2015, the individual grave was located and the human remains recovered¹⁶. The skeleton was in a poor state of preservation but a number of other materials and items survived. These included black Bakelite buttons from the jacket he wore, as well as a piece of woollen fabric from a sweater. Along the right side of the body, several objects were recovered, possibly contained within a backpack, such as a fork and spoon set (Figure 5), two full ammunition magazines, and four loose projectiles. The identity of the combatant was known from the disclosure made to the relatives, but genetic tests were carried out to confirm the identity of P.U.P. who died at the age of 22 years.

¹⁴ <https://www.lavanguardia.com/politica/20180721/451006792580/recuperan-los-restos-de-246-soldados-de-la-guerra-civil-en-fosas-del-ebro.html> (accessed October 2020)

¹⁵ <https://tribunadarqueologia.blog.gencat.cat/2020/06/12/propera-conferencia-de-la-tribuna-darqueologia-2019-2020-en-linia-pernafeites-miravet-ribera-debre-i-cementiri-vell-el-soleras-garrigues-dos-casos-de-fosses-de-la-gue/> (accessed October 2020)

¹⁶ https://elpais.com/politica/2015/12/05/actualidad/1449336279_795779.html (accessed October 2020)



Figure 5. Set of nickel silver spoon and fork from Mendata (Bizkaia).



Case Study 2: Mount Altun

This case corresponds to a section of trench used to bury the bodies of five soldiers (Figure 6) who were killed in action in the first half of April 1937 on Mount Altun (Zeanuri, Bizkaia). This zigzagged shaped trench is 0.60m wide and over 10m long. The skeletal remains were not in a poor state of preservation and incomplete in part due to the action of scavengers. The descriptions below outline the archaeological context, the position of the body, the biological profile and information on trauma from the forensic anthropological analysis, as well as the identification of the deceased.

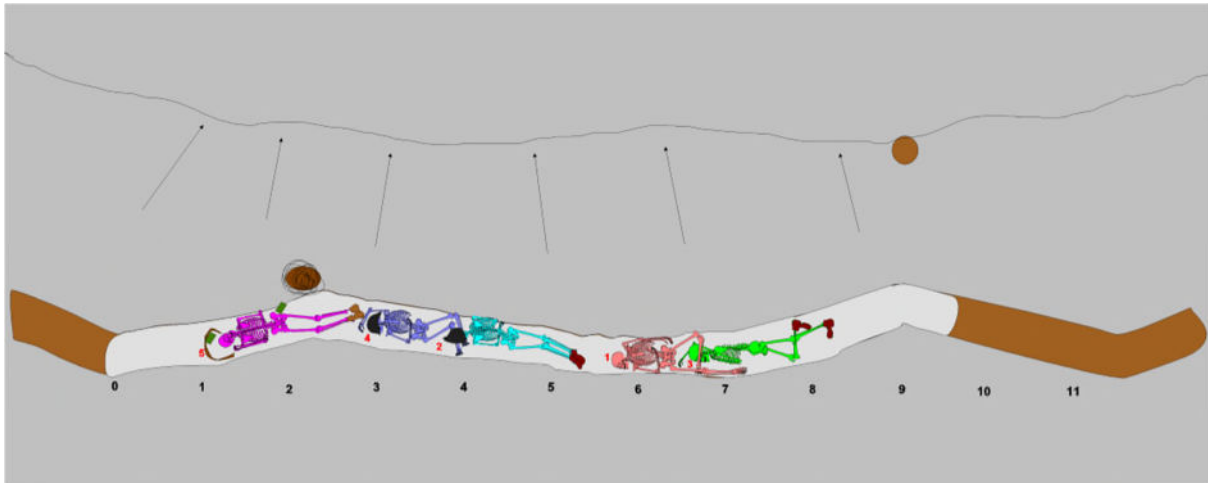


Figure 6. Mount Altun (Zeanuri, Bizkaia). Schematic drawing of the trench and the individuals buried within it.

Individual 1 was buried in a supine position with the right arm flexed over the trunk and the left arm extended. The right leg was extended and the left bent at an angle, with the left foot under the lower right limb. The distal third of the left femur presented a spiral fracture. This male skeleton was wearing shoes and recovered around him were 16 bullet cases, two cartridges and a bullet. A helmet was found on the body, as well as an aluminium plate inside which a canteen was embedded and deformed. Associated also with this individual, was an identification plate with the number 21967. Archival research into Payrolls, provided a possible identification from the identity disc. This hypothesis was corroborated by DNA analysis as soldier P.S.M.B., a militiaman of the 4th Company of the Communist Battalion No. 10 Facundo Perezagua.

Individual 2 was found in a prone position, with the arms flexed below the thorax. The lower extremities were extended, and the knees and feet were together, adapting to the shape of the trench. The forensic anthropological analysis provided an estimated age-at-death of less than 25 years from the observation of the medial clavicle, which had not completely fused. Associated objects as documented during the excavation included a metal spoon with a bent handle, a comb with a sheath made of celluloid imitation tortoiseshell, a celluloid cigarette holder of various colours (Figure 7), a deformed helmet found over the skull, boots with studs and an identification tag with the number 11709 (Figure 8). The latter identified an individual with the initials P.G.G., and this identity was also confirmed through DNA analysis. This individual belonged to the same battalion as Individual 1.



Figure 7. Coloured cigar mouthpiece. Mount Altun Trench.



Figure 8. Identification tag number 11709 corresponding to soldier P.G.G.

The body of Individual 3 was lying on its right side, with the right leg flexed below the left. Anthropological analysis in the laboratory provided an age at death for this male individual as less than 25-30 years. Among the objects recovered in relation to him, there were a belt, buttons, boots, an aluminium plate, a spoon and fork (Figure 9), a mouthpiece of a wine boot, part of a canteen, a cartridge clip and an identification tag with the number 12875. This soldier belonged to the same battalion as the previous two individuals.



Figure 9. Plate, spoon and fork recovered from Monte Altun, as found.

Individual 4 was in a supine position with the left arm flexed above the head. The lower limbs were flexed because they presented perimortem fractures (Figure 10). Due to the incomplete fusion of the clavicles, an age-at-death of less than 25 years was estimated. This soldier carried a bent iron spoon, a belt with a buckle, several silver coins issued by the Government of Euzkadi in 1937, a fragment of mirror and a perfectly preserved helmet. Several bones of the upper and lower limbs evidenced *peri-mortem* diaphyseal fractures. In this case, an identification disc was not located, but with the existing documentation available on the list of casualties buried there, the identification by the anthropologist was thought to be that of V.F.S., which was also confirmed later by DNA analysis.



Figure 10. *Peri-mortem* fractures to the right femur at the level of the proximal third and the middle third of the shaft.

Finally, the skeletal remains of Individual 5 were affected by the roots of a pine tree that had grown through the bones, causing fragmentation and erosion. Associated with this individual were two complete cartridge belts (Figure 11), in addition to straps, belt, buckles and boots. He was identified as J.M.A.R.



Figure 11. Restored holster with ammunition.

These examples provide a quick overview of the work that archaeologists and anthropologists have undertaken from the recovery of the remains and associated artefacts to the process of identification. It also highlights how the identification of civil war victims requires a combination of archaeological information, forensic anthropological analysis [29] and ultimately DNA analysis [30].

Conclusion

This paper has focused on the combatants from the Spanish Civil War, mainly Republicans, rather than the bulk of the exhumations and published archaeological and anthropology literature on the extrajudicial executions of civilians. The archaeological work carried out to date show that the clandestine graves of combatants are located in areas where the confrontations were more intense; in particular distributed in three geographical areas of the Iberian Peninsula. These burials or depositions are located in a number of environments and contexts, including mountains, chasms, battlefields, trenches, etc. These burials are varied, ranging from shallow individual graves, surface depositions, to burials in groups within trenches. The search and location of these human remains has been aided by the witness

information or testimonies of local residents, as well as archaeological evaluations using geophysics and other techniques.

The soldiers were buried with their gear and sometimes personal effects, as can be seen from the military material culture such as clothing and weapons associated with the human remains. In contrast to the executed civilians from the Spanish Civil War clandestine graves [19, 31], the identification of these combatants is facilitated by the discovery of identity discs. The interdisciplinary contribution from archaeology, forensic anthropology, historical documentation and archival research; in addition to DNA analysis where possible, has enabled a number of identifications, and provided information on the battalion, date of death, and cause and manner of death.

The Human Rights investigations undertaken by (forensic) archaeologists and forensic/physical anthropologists, as part of a wider team including forensic pathologists, psychologists, and social anthropologists; has resulted in a number of experienced and highly skilled teams in Spain who constantly and tirelessly undertake this work. These scientists should follow forensic protocols as has been recommended in the past [28]¹⁷, in particular around the chain of custody in the documentation and identification of individuals and other evidence. These exhumations have been carried out, ultimately, by the tireless work of professionals and volunteers from a number of disciplines with the aim of identifying the missing, return the remains to relatives where possible and provide these combatants with a respectful and dignified burial.

Acknowledgements

This paper is the result of the work undertaken by all the Anthropology team members of SCA, as well as the surveying work undertaken by Euskal Prospektore Taldea. The exhumations undertaken in the Basque Country have been carried out under the direction of the *Instituto de la Memoria, de la Convivencia y los Derechos Humanos del País Vasco- GOGORA* (<https://www.gogora.euskadi.eus/aa82-home/es/>).

¹⁷ See also http://www.sc.ehu.es/scrwwsr/Medicina-Legal/_private/AnPat.htm (accessed October 2020)

References

- [1] Groen, W.J.M., Márquez-Grant, N. and Janaway, R.C. (eds), *Forensic Archaeology: A Global Perspective*. John Wiley & Sons, Chichester.
- [2] Loe, L., Barker, C., Brady, K., Cox, M. and Webb, H. 2014. *'Remember Me to All': The Archaeological Recovery and Identification of Soldiers Who Fought and Died in the Battle of Fromelles 1916*. Oxford Archaeology, Oxford.
- [3] Márquez-Grant, N., Wessling, R., Öfele, A. and Moore, V. 2019. Buscando al soldado desconocido: la identificación de desaparecidos en la Primera Guerra Mundial. *Mètode Science Studies Journal*, 101: 73-81.
- [4] Etxeberria, F., Herrasti, L. and Bandres, A. 2005. Muertes violentas determinadas a través de los estudios de paleopatología. *Munibe (Antropología-Arkeologia)*, 57: 345-357.
- [5] Herrasti, L., Etxeberria, I., Unanua, R., Erce A., Sesma, J., García, J. and Etxeberria, F. 2017. Una fosa común de la Guerra de la Independencia en Navarra: interpretación de la causa de muerte. In: M. Díaz-Zorita Bonilla, J. Escudero Carrillo, I. López Flores, J. Lucena Romero, E. Mora Rosa and S. Robles Carrasco (eds), *Paleopatología y Bioarqueología: Contextualizando el Registro Óseo. Actas del XIII Congreso Nacional de Paleopatología, Écija (Sevilla) 1-4 de octubre de 2015*. Andaluza de Papel. Pages 189-197. <https://asociacionpaleopatologia.es/actas-congresos-aep/>
- [6] Etxeberria, F. 1999. Surgery in the Spanish War of Independence (1807-1813), between Desault and Lister - Chirurgia nella Guerra di Indipendenza (1807-1813), tra Desault e Lister. *Journal of Paleopathology*, 11: 25-40.
- [7] Etxeberria, F. and Herrasti, L. 1991. War injuries in a field hospital dating to the beginning of the nineteenth century in the Basque Country (Spain). *International Journal of Osteoarchaeology*, 1: 279-282.
- [8] Herrasti, L., Etxeberria, F. and Berjón, M.A. 2012. Muerte violenta en 1822: una fosa común en Ocio (Zambrana, Álava). *Munibe (Arkeologia-Antropologia)*, 63: 345-366.
- [9] Preston, P. 2016. *La Guerra Civil Española*. Debate, Barcelona.
- [10] González Ruibal, A. 2016. *Volver a Las Trincheras: Una Arqueología de la Guerra Civil Española*. Alianza Editorial, Madrid.
- [11] Gallego-Vila, L. and Solé, Q. 2018. Edificios heridos. Propuesta para una arqueología de los bombardeos de la Guerra Civil Española (1936-1939). *E-rph: Revista Electrónica de Patrimonio Histórico*, 23: 1-25.

- [12] Ramos Ruiz, J. 2018. La arqueología de la Guerra Civil Española a Cataluña. *Revista del Seminario de Arqueología de la Universidad Pablo de Olavide de Sevilla*, 17: 133-154.
- [13] Beevor, A. 2011. *La Guerra Civil Española*. Booket, Barcelona.
- [14] Julià Diaz, S. (ed). 1999. *Víctimas de la Guerra Civil*. Temas de Hoy, Barcelona.
- [15] Espinosa, F. 2010. *Violencia Roja y Azul. España 1936-1939*. Ed. Crítica, Barcelona.
- [16] Anderson, P. and Del Arco, M. 2014. *Lidiando con el Pasado. Represión y Memoria de la Guerra Civil y el Franquismo*. Ed. Comares, Granada.
- [17] Etxeberria, F. (ed). 2012. Antropología Forense de la Guerra Civil Española. Special Issue in *Boletín Galego de Medicina Legal y Forense*, 18.
- [18] Etxeberria, F. and Solé, Q. 2019. Fosas comunes de la Guerra Civil en el siglo XXI: antecedentes, interdisciplinariedad y legislación. *Historia Contemporánea*, 60: 401-438.
- [19] Etxeberria, F., Herrasti, L., Márquez-Grant, N., García-Rubio, A. and Jiménez, J. 2016. Mass graves from the Spanish Civil War: exhumations, current status and protocols. *Archaeological Review From Cambridge*, 31: 82-102.
- [20] Solé, Q. 2017. The valley of the fallen: a New Escorial for Spain. *Human Remains and Violence*, 3: 3-21.
- [21] Carman, J. 2013. *Archaeologies of Conflict*. Bloomsbury, London.
- [22] Arteche, J. 1970. *El Abrazo de los Muertos*. Editorial Icharopena, Gipuzkoa.
- [23] Etxeberria, F., Serrulla, F. and Herrasti, L. 2014. Simas, cavernas y pozos para ocultar cadáveres en la Guerra Civil española (1936-1939). Aportaciones desde la Antropología Forense. *Munibe (Antropología-Arkeología)*, 65: 269-288.
- [24] Márquez-Grant, N., Rissech, C., López-Costas, O., Alemán, I. and Caro Dobón, L. 2011. Spain/España. In: N. Márquez-Grant and L. Fibiger (eds), *The Routledge Handbook of Archaeological Remains and Legislation: An International Guide to Laws and Practice in the Excavation and Treatment of Archaeological Human Remains*. Routledge, Abingdon. Pages 423-438.
- [25] Prieto, J.L. 2016. A history of forensic anthropology in Spain. In: S. Blau and D.H. Ubelaker (eds), *Handbook of Forensic Archaeology and Anthropology*. Routledge, New York, 2nd Edition. Pages 52-64.
- [26] Herrasti, L., Sampedro, A.J., Dieguez, J., Etxezarraga, J., Irusta, A., Jimenez, J., Rebolledo, I., Sardon, A., Sardon, E. and Etxeberria, F. 2014. Placas de identificación de combatientes de la Guerra Civil española (1936-1937), recuperadas en exhumaciones de escenarios bélicos en el País Vasco. *Munibe (Antropología-*

Arkeologia), 65: 289-312.

[27] Etxeberria, F., Herrasti, L., Serrulla, F. and Márquez-Grant, N. 2015. Contemporary exhumations in Spain: recovering the missing from the Spanish Civil War. In: W.J.M. Groen, N. Márquez-Grant and R.C. Janaway (eds), *Forensic Archaeology: A Global Perspective*. John Wiley & Sons, Chichester. Pages: 489-497.

[28] Irujo, X. 2015. *Gernika, 1937. The Market Day Massacre*. University of Nevada Press, Reno, NV.

[29] Ríos, L., Casado Ovejero, J.I. and Puente Prieto, J. 2010. Identification process in mass graves from the Spanish Civil War I. *Forensic Science International*, 199: e27-e36.

[30] Baeta, M., Núñez, C., Cardoso, S., Palencia-Madrid, L., Herrasti, L., Etxeberria, F. and De Pancorbo, M.M. 2015. Digging up the recent Spanish memory: genetic identification of human remains from mass graves of the Spanish Civil War and posterior dictatorship. *Forensic Science International: Genetics*, 19: 272-279.

[31] Etxeberria Gabilondo, F. 2012. Exhumaciones contemporáneas en España: las fosas comunes de la Guerra Civil. *Boletín Galego de Medicina Legal e Forense*, 18: 13-28.

Spanish Civil War: the recovery and identification of combatants

Herrasti, Lourdes

2021-03

Attribution-NonCommercial-NoDerivatives 4.0 International

Herrasti L, Márquez-Grant N, Etxeberria F. (2021) Spanish Civil War: the recovery and identification of combatants. *Forensic Science International*, Volume 320, March 2021, Article number 110706

<https://doi.org/10.1016/j.forsciint.2021.110706>

Downloaded from CERES Research Repository, Cranfield University