

A preliminary study into injuries due to non-perforating ballistic impacts into soft body armour over the spine

Rosalind M. Jennings¹, Chris Malbon², Dr Fiona Brock¹, Lt. Col. Stuart Harrison³, Dr Debra J. Carr^{2,4}

1. Cranfield Forensic Institute, Cranfield University

2. Impact and Armour Group, Department of Engineering and Applied Science, Cranfield Defence and Security, Cranfield University

3. Academic Department of Military Surgery and Trauma, Royal Centre for Defence Medicine, Birmingham.

4. Now at: Defence and Security Accelerator, Porton Down, Salisbury, SP4 0JQ, UK.

Correspondence to:

Name: Dr D J Carr

Address: Defence and Security Accelerator, Porton Down, Salisbury, SP4 0JQ, UK.

Email: dicarr@dstl.gov.uk

Keywords: Pencilling, Police, BABT, HG1/A, spinal, fracture, soft tissue wounds

Abstract

The UK Home Office test method for ballistic protective police body armours considers anterior torso impacts to be the worst case scenario and tests rear armour panels to the same standards as front panels. The aim of this paper was to examine the injuries from spinal behind armour blunt trauma (BABT) impacts. This study used a cadaveric 65 kg, female pig barrel and 9 mm Luger ammunition (9 x 19 mm, FMJ Nammo Lapur Oy) into HG1/A + KR1 soft armour panels over the spine. Injuries were inspected and sections removed for x-radiography and micro-CT assessment.

All shots over the spine resulted in deep soft tissue injuries from pencilling of the materials. The wounds had embedded fabric debris which would require surgery to remove resulting in increased recovery time over injuries usually seen in anterior torso BABT impacts, which are typically haematoma and fractured ribs. The shot with the deepest soft tissue wound (41 mm) also resulted in a fractured spinous process. Shots were also fired at the posterior and anterior rib area of the pig barrel, for comparison to the spine. Similar wounds were seen on the shots to the posterior rib area while shallower, smaller wounds were seen on the anterior and one anterior rib shot resulted in a single, un-displaced rib fracture. The anatomical differences between pigs and humans would most likely mean that injury to a human from these impacts would be more serious.

Introduction

Body armour covers the torso and can be tailored to protect wearers from a range of threats including fragmentation, sharp-weapons, low velocity (handgun) and high velocity (rifle) ammunition ¹. The most common armour worn by routine patrol officers is HG1/A + KR1 which provides protection from low velocity handguns and sharp weapons using a fabric based 'soft' solution ¹. The level of protection provided to the posterior torso is the same as the anterior. Non-penetrating impacts onto body armour will often result in behind armour blunt trauma (BABT) ^{2,3}. BABT refers to a non-penetrating injury which is the result of rapid deformation of body armour from a ballistic impact ². During BABT there is an initial compression wave (high amplitude, short duration) as the bullet impacts the armour and can result in injuries such as rib fractures and internal contusions. This is followed by a compression wave from the deformation of the rear face of the armour into the body which can cause skin abrasions and contusions ^{4,5}. The deformation of the armour is used as a measure in body armour testing and is a record of the depth of an indentation formed in Roma™ Plastilina no. 1 clay when there is a non-penetrating impact onto body armour mounted in front of the clay ^{6,7}. The depth of this indentation is called the back face signature (BFS) and is typically hemispherical in shape. The standards for ballistic and knife resistant body armour for civilian law enforcement agencies in the UK are managed by the Home Office Centre for Applied Science and Technology (CAST). HG1/A body armour is currently tested against 9 mm and 0.357" ammunition at velocities within range of 365 ± 10 m/s and 390 ± 10 m/s respectively and has a maximum BFS depth of 44 mm for the armour to pass testing ⁷. Many studies measure the BFS and attempt to correlate this to injuries in humans however there is no proven correlation between these two factors ⁸. There are case studies of contusions from non-penetrating impacts onto body armour and reports of

broken ribs however there have been no reports of BABT resulting in life threatening injuries^{3,9}.

Pencilling is an injury mechanism specific to BABT impacts onto soft body armour. Instead of the usual hemispherical BFS the body armour, and clothing underneath, form a more tapered deformation which penetrates into the soft tissue directly under the body armour¹⁰. The resulting injury can appear similar to a ballistic entry wound and has been noted during research into BABT as well as studied in its own right¹⁰.

Predominantly research into BABT has considered projectiles fired at the anterior rib cage and abdomen^{2-4,11-18} and there is currently a limited understanding of the injury mechanisms involved in BABT impacts over the spine. Only three peer reviewed journal papers were found concerning BABT shots over the spine and they varied widely in armour type, ammunition, velocity and data measurements taken¹⁹⁻²¹.

Although human cadavers and live animals are occasionally used in ballistic testing there are considerable moral and ethical issues involved with both. Cadaveric pig tissue has been used frequently for both ballistic and medical research due to its similarities with human tissue and it has become an acceptable substitute for the human torso^{9,22-25}.

The aim of this paper was to examine the injuries from spinal BABT impacts. This study used a 65 kg, female pig barrel and 9 mm Luger ammunition (9 x 19 mm, FMJ Nammo Lapur Oy) into HG1/A + KR1 soft armour panels over the spine. Injuries were inspected, and sections removed for x-radiography and micro-CT assessment.

Ethical approval for the work was granted by Cranfield University (approved 16/11/2016, ref: CURES/2151/2016)


Materials and methods

Materials

A food grade, cadaveric pig barrel was collected on the morning of the test day.

A standard UK police polo shirt (50% polyester, 50% Nano Kool), and body armour carrier vest were used in combination with HG1/A + KR1 body armour test panels (fig 1).

Figure 1: a) Typical police polo shirt with carrier vest over the top and b) standard UK ballistic test panel of HG1/A + KR1 body armour



The ammunition used was 9 mm Luger (9 x 19 full metal jacket; made by - Nammo Lapur Oy, Finland), (fig 2).



Figure 2: 9 mm Luger FMJ ammunition side and end on view

Method

The pig barrel was photographed and soft tissue (skin and fat layers) thickness measured with forensic scale prior to testing. The barrel was placed on a clear topped table 10 m down range with the spine facing the end of the muzzle. The pig barrel was loosely tied to a beam to keep it upright during impact but allow natural movement (fig 3). An Enfield Number 3 Proof Housing with a 127 mm barrel fitted was used to fire the ammunition; this is a standard apparatus used in ballistic test ranges (fig 4). The pig barrel was covered in the polo shirt and then the body armour, in carrier vest, secured over the spine. Shots were aimed to hit the armour over a vertebra. All shots were aimed at least 50 mm from other shots resulting in five shots along the spine. The projectile impact velocities were recorded using a Weibel W-700 Doppler radar. A Phantom V1212 high-speed video camera recorded the impact events from underneath (20,000 frames per second, 5 μ s exposure time, 512 x 384 frame resolution).

Figure 3: Testing set up before clothing and body armour put on



Figure 4: Proof housing with 127 mm barrel and Weibel Doppler radar to the left facing down the range



Analysis

Photographs were taken of damage to the body armour and clothing and of the resulting wounds to the pig barrel using a Nikon D300 SLR digital camera with 55 mm lens.

Post ballistic testing debris was collected from the pig barrel wounds which were measured and photographed with a forensic scale. The barrel was then dissected, using scalpel and bolt cutters, by removing ribs and then cutting between vertebra at least one above and below the impact location. Damage to the polo shirt, carrier vests and body armour panels were also photographed and measured, bullets and fragments retrieved where possible and level of penetration into the armour noted.

The spine sections were frozen after dissection and defrosted 24 hr before being x-radiographed (120 - 130 kV, 45 - 50 μ A, 500 ms exposure, 64 frame average) and micro-CT scanned (100 kV, 45 μ A, 500 ms exposure) using a Nikon Metris X-Tek XT H225 scanner.

Data was collected with Inspect-X software version 3.1.12 and analysed with VG Studiomax software version 2.1. Only those sections which showed fractures on x-radiographs or were believed to have interior damage from visual inspection were subject to micro-CT scanning.

Radiographs, micro-CT images and wound / debris photographs were reviewed by a military neurosurgeon (SH) who commented on the level of injury, potential recovery time and long-term outcomes.

Results

Impacts

The mean impact velocity for the five shots was 373 m/s (SD = 2) and all velocities were within the tolerances specified in the UK ballistic testing guidelines ⁷ (table 1).

Shot four perforated the armour panel but the pig barrel shifted after set up and the shot impacted less than 50 mm from the edge of the armour and missed the spine, therefore this shot is not considered for the rest of this paper. The other shots were all deemed valid.

Table 1: Individual shot information

Shot No.	Velocity (m/s)	Soft tissue wound depth (mm)	Soft tissue wound external dimensions (mm)	X-radiograph interpretation	Micro-CT scan interpretation
1	376	16	17 x 17	No fractures visible	Not scanned
2	373	41	14 x 22	Possible spinous process fracture	Spinous process fracture
3	374	17	15 x 20	Bony fragment on anterior side of vertebral body	Anterior bony fragment
4	371	-	-	Not X-rayed	Not scanned
5	373	21	19 x 35	No fractures visible	Not scanned

Body armour and clothing

For each spine shot the rear of the carrier vest was perforated by the rear face of the deformed armour (fig 5). Spine shots one, three and five penetrated 14 layers of the soft armour while spine shot two penetrated 20 layers.

The polo shirt was damaged under all the impact points with holes ranging from 14 mm x 14 mm to 17 mm x 25 mm.

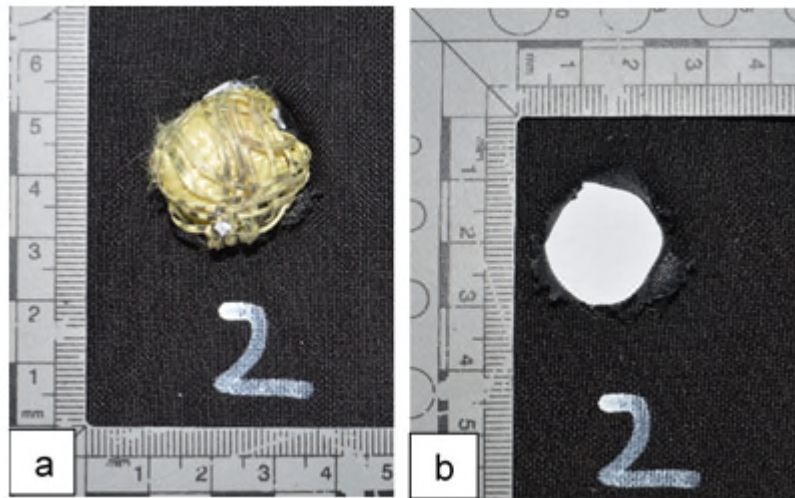


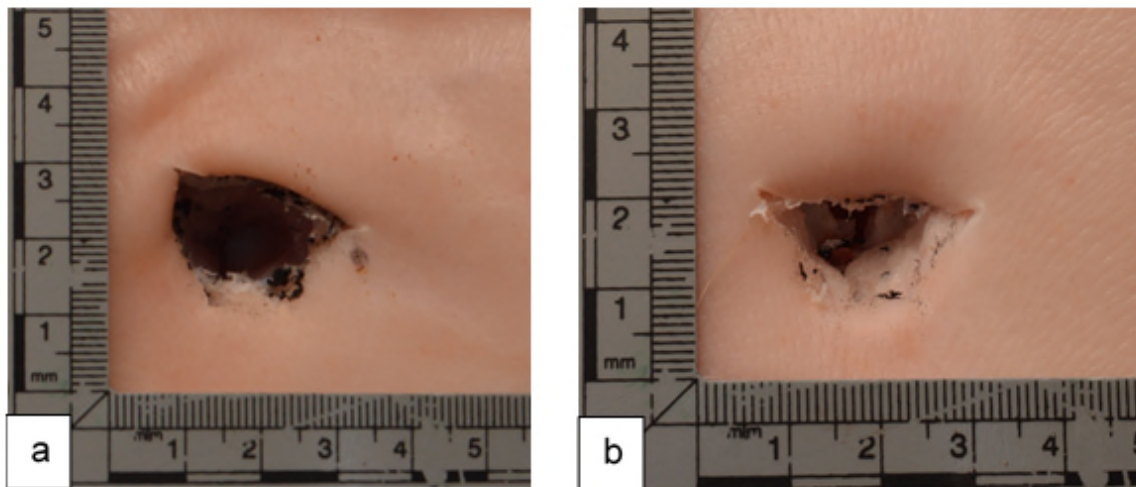
Figure 5: Rear of carrier vest used for shot 2 showing a) the armour still perforating through the fabric and b) damage to the vest after armour removed

Wounds

The mean thickness of the pig barrel soft tissue was 18 mm (SD = 5) at the neck end and 10 mm (SD = 1) at the pelvis end with thickest measurements (25 mm) over and beside the spine which is 10 times thicker than the soft tissue layers on an average human back^{26,27}.

All of the spine shots resulted in soft tissue wounds from the pencilling mechanism of the body armour. Measurements were taken for height, width and depth of the wounds (Table 1). Spine shot 2 resulted in the deepest wound at 41 mm and all wounds had fabric debris around the outer edges as well as embedded within (fig 6).

Figure 6: Soft tissue wounds in the pig barrel from pencilling showing debris around outer edge as well as embedded inside, a) shot 5 and b) shot 2



Discussion

Medical review

The soft tissue wounds, created by the pencilling of the armour, perforated through the skin into the tissue beneath and were similar in appearance to fragment injuries seen in both Iraq and Afghanistan associated with explosive devices. The wounds would require surgery under general anaesthetic in order to remove debris and debride any dead tissue.

Depending on the level of debris found the wound may not be primarily closed, and instead delayed closure performed at 48 hours. The greatest risk to the patient is from infection if the wound was not debrided effectively during surgery and would need to be monitored closely. These wounds would be expected to be fully healed within two weeks and would require a course of anti-biotics and activity modification to allow healing. The extent of any contusions from these injuries is unknown as cadaveric tissue, albeit freshly killed, was used but it is expected there would be both external and possibly internal bruising at the impact point.

From the x-radiographs and micro-CT scans there was no evidence of spinal canal or cord damage for any of the shots. Spine shot two resulted in a spinous process fracture (fig 7) and spine shot three shows evidence of a bony injury to the anterior side of the vertebral body without any accompanying fracture through the body (table 1) and is believed to be un-associated damage. An isolated stable fracture of the spinous process is considered of minimal impact and is normally treated conservatively without medical intervention. The injury may cause pain on mobilisation for the first few weeks but recovery time would be anticipated to be around six - eight weeks for full healing. For each of the shots a full recovery would be expected.

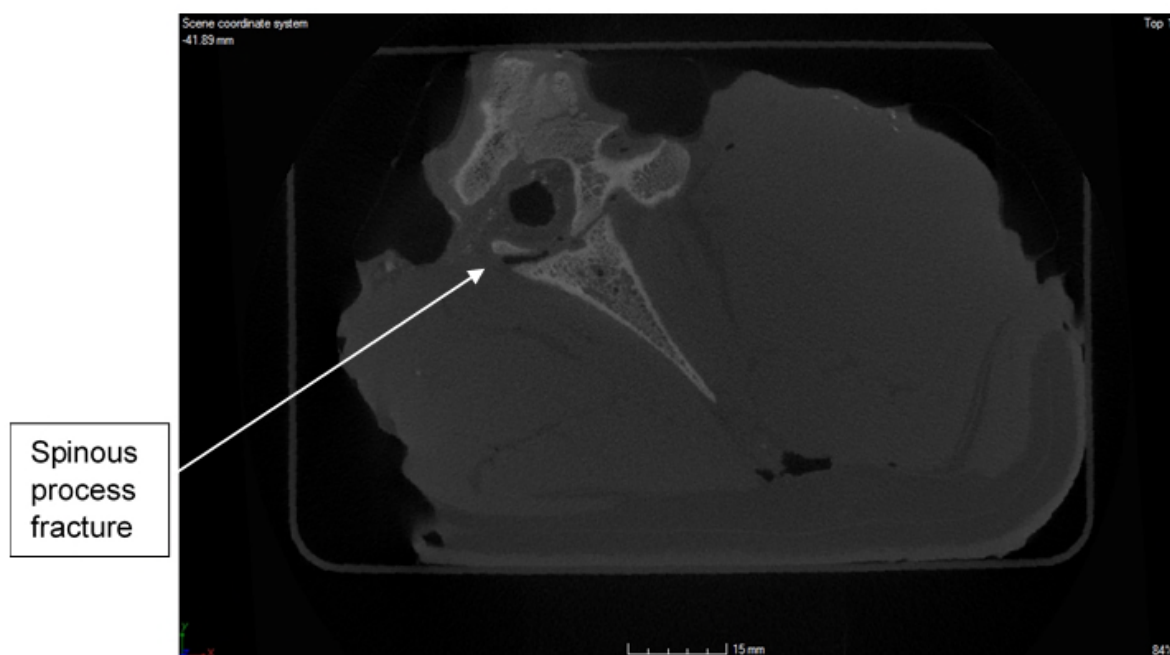


Figure 7: Micro-CT slice through spine shot 2 showing fracture at base of spinous process

General discussion

To the best of knowledge this is the first time this particular research has been conducted in this manner and therefore the results cannot be directly compared to any other studies. The results do agree with the only other three papers found that contain an aspect of BABT impacts over the spine¹⁹⁻²¹. The soft tissue injuries seen during this research appear consistent with injuries formed by pencilling; a tapered mass of armour penetrating into the body. It is presumed that the reason for the formation of this injury type is the compact nature of the tissue on the back and the bony structure of the spine underneath. This does not allow a wider dissipation of the energy from the rear face of the armour such as may be gained from the soft, flexible abdomen or articulated ribs. This is reflected by the smaller soft tissue wounds from the anterior rib shots.

It is unknown if the spinous process fracture was a result of the initial impact or from the penetration of the armour into the soft tissue. It could be that the combination of these two mechanisms first weakened and then applied force to the spinous process causing the fracture. The bony fragment seen on shot three is on the anterior side of the vertebral body and although the exterior of that section showed no damage it is believed that this may be previous damage or a weakened area as there is no corresponding vertebrae process or body fracture and the fragment has come cleanly away.

Due to this different injury mechanism for posterior BABT impacts the recovery time required by an injured officer would likely be longer than that typically reported for anterior torso BABT²⁸⁻³⁰. The wounds are likely to require surgery and two weeks for full recovery and a police officer injured in this manner would also likely be on restricted duties for a period. Complications of infection from debris in the wound could extend this time further.

If there is a spinous process fracture then the recovery time increases to at least two months off work.

This research used a combination of standard police body armour and the lowest level threat tested by CAST (9 mm ammunition at approx. 365 m/s) and for each spine shot soft tissue injuries occurred. It is possible therefore that for the higher level threat for HG1/A (0.357 " ammunition at approx. 390 m/s) there may be even greater damage. CAST currently test front and rear armour panels under the same conditions and requirements which could mean that rear armour is not being tested with the correct BFS limits. The current BFS limit for HG1/A armour panels is 44 mm, the assumption being this would not result in serious injury if such an impact occurred on a human, yet spine shot two created a BFS of 41 mm which resulted in a fracture to the spine and deep soft tissue injury on a pig barrel.

Although there are many similarities between porcine and human tissue and bone there are also significant differences which should be addressed here:

- The human spine is closer to surface
- Humans have thinner skin and typically less fat above the spine
- Human spinous processes are smaller and thinner
- The pig barrel is skeletally immature compared to an adult human

It is likely that the BAPT impacts seen in this study would inflict greater damage on a human than seen on the pig barrels. The pigs used in this study had skin and fat layers between five to ten times thicker than an average human's skin which is around 2.4 mm thick ^{26,27,31}. The thinner skin of humans will be broken more easily than pigs and give less resistance to penetration of the armour mass resulting in deeper soft tissue wounds. With the spine

closer to the surface it could reduce the depth of soft tissue wounds on direct impacts over bone as it will be stopped sooner but this would increase the likelihood of a spinous process or vertebra fracture. The smaller size of human's spinous processes could give greater resilience to fracture as there is less surface area to impact but it is more likely that the thinner nature of the processes and their position closer to the surface would make them more susceptible to fracture. The smaller size of the spinous process also reduces protection for the vertebral body behind it. For the deepest wound seen in this study (41 mm) there would be a greater risk of more serious, unstable, vertebral fractures involving the vertebral body for humans. The skeletal immaturity of the pig means that the bone is more pliable than humans which could give the pig barrel greater resistance to fracture ^{32,33}.

Limitations and considerations

The main limitation of the study is the small data size of four shots which places caveats on the conclusions that can be drawn. Further work is recommended looking at spinal BAPT with these same armour / threat combinations.

The medical review was limited by artifacts within the micro-CT images due to the large amount of soft tissue, and associated water content, as well as some residual metal debris which affected the clarity. There were a limited number of radiographs taken either laterally or anterior - posterior meaning that other angles were not available to be viewed if needed. This meant only clear fractures could be reported while smaller damage may have been missed.

Conclusions

HG1/A + KR1 soft armour BABT impacts over the spine result in a different injury mechanism and larger, deeper wounds compared to anterior soft armour BABT impacts and can require a longer recovery time and more serious medical intervention. The baseline rib shots resulted in commonly reported anterior BABT wounds as expected and shows the test method is effective. Impacts onto humans would most likely result in more serious injuries than those seen here on cadaveric pig tissue.

The current UK ballistic testing of rear armour panels to the same standard as front panels and a BFS limit of 44 mm does not take into account this different injury mechanism and the possibility of serious injury with BFS depths under 44 mm over the spine. Due to the difference in spinal BABT injury mechanism compared to anterior BABT impacts there should be a review of ballistic testing in regards to the possibility of different testing methods for rear armour panels or a consideration for lowering the HG1/A BFS from 44 mm down to 25 mm in line with all the other armour types tested.

This research was limited to looking only at the combination of 9 mm ammunition with HG1/A + KR1 soft armour, therefore it is not possible to conjecture about other armour / ammunition combinations and their resulting injury mechanisms.

References

1. Tobin L, Iremonger M. *Modern Body Armour and Helmets: An Introduction*. Canberra: Argos Press; 2006.
2. Cannon L. Behind Armour Blunt Trauma - An Emerging Problem. *J R Army Med Corps*. 2001;147(MARCH 2001):87-96. doi:10.1136/jramc-147-01-09
3. Carr DJ, Horsfall I, Malbon C. Is Behind Armour Blunt Trauma a Real Threat to Users of Body Armour? A Systematic Review. *J R Army Med Corps*. 2016;162(1):8-11. doi:10.1136/jramc-2013-000161
4. Sarron JC, Destombe C, Gotze H, Mayorga M. Physiological Results of NATO BABT Experiments. In: *Personal Armour Systems Symposium*. Colchester; 2000.
5. van Bree J, Gotts P. The "Twin Peaks" of BABT. In: *Personal Armour Systems Symposium*. Colchester; 2000.
6. Croft J. PSDB Body Armour Standards for UK Police: Part 2 Ballistic Resistance. 2003.
7. Croft J, Longhurst D. *HOSDB Body Armour Standards for UK Police (2007) Part 2: Ballistic Resistance.*; 2007.
8. Anderson I, Knudsen P, Sarron JC, van Bree J, Gotts P, Waclawik S. A review of the work of the Task Group on Behind Armour Blunt Trauma. In: *Personal Armour Systems Symposium*. The Hague; 2002.
9. Carr D, Horsfall I. *Behind Armour Blunt Trauma: A Literature Review (CU/DEAS/HGDG/2166/12).*; 2012.

10. Lewis E, Johnson P, Bleetman A, et al. An Investigation to Confirm the Existence of “Penciling” as a Non-penetrating Behind Armour Injury. In: *Personal Armour Systems Symposium*. The Hague; 2004.
11. Lewis EA, Horsfall I, Watson CH. A Comparison of the Behind Armour Blunt Trauma Effects between Ceramic Faced and Soft Body Armours Caused by Ballistic Impact. In: *Personal Armour Systems Symposium*. The Hague; 2002.
12. Magnan P, Sarron JC, Vassout P, et al. Physiological Results of French BABT Experiments - Comparison with Non Lethal Kinetic Weapons. In: *Personal Armour Systems Symposium*. The Hague; 2004.
13. Gryth D, Rocksén D, Persson JKE, et al. Severe Lung Contusion and Death after High-Velocity Behind-Armor Blunt Trauma: Relation to Protection Level. *Mil Med*. 2007;172(10):1110-1116. doi:10.7205/MILMED.172.10.1110
14. Merkle AC, Ward EE, O’Connor J V, Roberts JC. Assessing Behind Armor Blunt Trauma (BABT) Under NIJ Standard-0101.04 Conditions Using Human Torso Models. *J Trauma, Inj Infect Critcial Care*. 2008;64(6):1555-1561. doi:10.1097/TA.0b013e318160ff3a
15. Prat N, Rongieras F, Sarron JC, Miras A, Voiglio E. Contemporary Body Armor: Technical Data, Injuries and Limits. *Eur J Trauma Emerg Surg*. 2012;38(2):95-105. doi:10.1007/s00068-012-0175-0
16. Roberts JC, Biermann PJ, O’Connor J V., et al. Modeling Nonpenetrating Ballistic Impact on a Human Torso. *Johns Hopkins APL Tech Dig (Applied Phys Lab*. 2005;26(1):84-91.
<https://extranet.cranfield.ac.uk/techdigest/TD/td2601/,DanaInfo=www.jhuapl.edu+R>

oberts.pdf.

17. Hewins H, Horsfall I, Watson CH. The Validation of a Thoracic and Abdominal Test Rig for BAPT Soft Body Armour Testing. In: *Personal Armour Systems Symposium*. New Orleans; 2008.
18. Shen W, Niu Y, Bykanova L, Laurence P, Link N. Characterizing the Interaction Among Bullet, Body Armor and Human and Surrogate Targets. *J Biomech Eng*. 2010;132(12):1-11. doi:10.1115/1.4002699
19. Goldfarb MA, Ciurej TF, Weinstein MA, Metker LRW. *Technical Report EB-TR-74073. A Method for Soft Body Armor Evaluation: Medical Assessment*. Edgewood Arsenal; 1975. <http://www.dtic.mil/dtic/tr/fulltext/u2/a005575.pdf>.
20. Bass CR, Salzar RS, Lucas SR, et al. Injury Risk in Behind Armor Blunt Thoracic Trauma. *Int J Occup Saf Ergon*. 2006;12(4):429-442. doi:10.1080/10803548.2006.11076702
21. Zhang B, Huang Y, Su Z, et al. Neurological, Functional, and Biomechanical Characteristics After High-Velocity Behind Armor Blunt Trauma of the Spine. *J Trauma Inj Infect Crit Care*. 2011;71(6):1680-1688. doi:10.1097/TA.0b013e318231bce7
22. Bozkus H, Crawford NR, Chamberlain RH, et al. Comparative Anatomy of the Porcine and Human Thoracic Spines with Reference to Thoracoscopic Surgical Techniques. *Surg Endosc Other Interv Tech*. 2005;19(12):1652-1665. doi:10.1007/s00464-005-0159-9
23. Busscher I, Ploegmakers JJW, Verkerke GJ, Veldhuizen AG. Comparative Anatomical Dimensions of the Complete Human and Porcine Spine. *Eur Spine J*. 2010;19(7):1104-

1114. doi:10.1007/s00586-010-1326-9
24. Prat N, Rongieras F, de Freminville H, et al. Comparison of thoracic wall behavior in large animals and human cadavers submitted to an identical ballistic blunt thoracic trauma. *Forensic Sci Int.* 2012;222(1-3):179-185. doi:10.1016/j.forsciint.2012.05.022
 25. Maiden NR, Musgrave I, Fisk W, Byard RW. Pig Organ Energy Loss Comparison Experiments Using BBs. *J Forensic Sci.* 2016;61(3):679-686. doi:10.1111/1556-4029.13056
 26. Laurent A, Mistretta F, Bottiglioli D, et al. Echographic Measurement of Skin Thickness in Adults by High Frequency Ultrasound to Assess the Appropriate Microneedle Length for Intradermal Delivery of Vaccines. *Vaccine.* 2007;25:6423-6430. doi:10.1016/j.vaccine.2007.05.046
 27. Ni Annaidh A, Bruyre K, Destrade M, Gilchrist MD, Ottnio M. Characterization of the Anisotropic Mechanical Properties of Excised Human Skin. *J Mech Behav Biomed Mater.* 2012;5(1):139-148. doi:10.1016/j.jmbbm.2011.08.016
 28. Carroll a W, Soderstrom C a. A New Nonpenetrating Ballistic Injury. *Ann Surg.* 1978;188(6):753-757. doi:0003-4932/78/1200/0753
 29. Wilhelm M, Bir C. Injuries to law enforcement officers: The backface signature injury. *Forensic Sci Int.* 2008;174(1):6-11. doi:10.1016/j.forsciint.2007.02.028
 30. Wayne State University. *Establishment of Interdisciplinary Working Group for Review of Kinetic Energy Munitions Final Report 2010.*; 2011. <https://www.ncjrs.gov/pdffiles1/nij/grants/236909.pdf>.

31. Harlick JC, Milosavljevic S, Milburn PD. Palpation Identification of Spinous Processes in the Lumbar Spine. *Man Ther.* 2007;12:56-62. doi:10.1016/j.math.2006.02.008
32. Cone SG, Warren PB, Fisher MB. Rise of the Pigs: Utilization of the Porcine Model to Study Musculoskeletal Biomechanics and Tissue Engineering During Skeletal Growth. *Tissue Eng Part C Methods.* 2017;23(11):763-780.
doi:<https://doi.org/10.1089/ten.tec.2017.0227>
33. Swindle MM, Makin A, Herron AJ, Clubb FJ, Frazier KS. Swine as Models in Biomedical Research and Toxicology Testing. *Vet Pathol.* 2012;49(2):344-356.
doi:10.1177/0300985811402846

A preliminary study into injuries due to non-perforating ballistic impacts into soft body armour over the spine

Jennings, Rosalind M.

2018-05-22

Attribution-NonCommercial-NoDerivatives 4.0 International

Jennings RM, Malbon C, Brock F, et al., (2018) A preliminary study into injuries due to non-perforating ballistic impacts into soft body armour over the spine. *Injury*, Volume 49, Issue 7, July 2018, pp. 1251-1257

<https://doi.org/10.1016/j.injury.2018.05.015>

Downloaded from CERES Research Repository, Cranfield University